

**2019 RHEUMATOLOGIC ULTRASOUND (RhUS)
CURRICULUM SUPPLEMENT
TO THE
AMERICAN COLLEGE OF RHEUMATOLOGY
2015 CORE CURRICULUM OUTLINE**

TABLE OF CONTENTS

- I. MEDICAL KNOWLEDGE
- II. PATIENT CARE
- III. PRACTICE-BASED LEARNING AND IMPROVEMENT
- IV. SYSTEMS-BASED PRACTICE
- V. INTERPERSONAL AND COMMUNICATION SKILLS
- VI. PROFESSIONALISM

- APPENDIX A. RhUS ENTRUSTABLE PROFESSIONAL ACTIVITY
- APPENDIX B. RhUS CURRICULAR MILESTONES
- APPENDIX C. RhUS TOOLBOX: ACTIVITIES AND ASSESSMENTS
- APPENDIX D. PEDIATRIC RHEUMATOLOGY SUPPLEMENT
- APPENDIX E: STANDARD SCANNING PROTOCOLS
- APPENDIX F: DOCUMENTATION TEMPLATE
- APPENDIX G: SOURCE DOCUMENTS

INTRODUCTION

This Rheumatologic Ultrasound (RhUS) curriculum will integrate into the 2015 ACR Core Curriculum in a manner appropriate to individual fellowship program curricula. Many of the components of the Core Curriculum are relevant to fellow education in RhUS and not duplicated in this document.

I. MEDICAL KNOWLEDGE

BASIC SCIENCES

- A. Identify the following areas of musculoskeletal anatomy
 1. Structures should include, but are not limited to the joints, tendons, ligaments, bursa, bone, cartilage, muscle, blood vessels, nerves, and fat
 2. Joint areas should include, but are not limited to the following: hand, wrist, elbow, shoulder, hip, knee, ankle, and foot
 3. Pediatric specific imaging: growth plates, secondary ossification centers, cartilage, and normal Doppler activity
- B. Identify musculoskeletal anatomy on a living person, including the dynamic action of the musculoskeletal system
- C. Correlate normal anatomic structures with their appearance on RhUS imaging
- D. Identify and demonstrate normal musculoskeletal anatomy, and common variants thereof, using RhUS in the adult and/or the pediatric patient

CLINICAL SCIENCES

- A. Identify the following pathology commonly seen in rheumatic disease states
 1. Joint: synovitis, effusion
 2. Tendon: tenosynovitis, paratendonitis, inflammation, tendinosis/degeneration, tear/rupture, enthesitis, nodule, calcification, subluxation or architectural abnormality
 3. Bursa: synovitis, effusion
 4. Bone: erosion, osteophyte
 5. Cartilage: calcification, crystalline deposition, thickness
 6. Nodules: tophus, rheumatoid nodule, ganglion
 7. Nerve: entrapment, hypertrophy
 8. Fibrous tissue: ligaments and fascia of particular importance to rheumatology, such as the plantar fascia and triangular fibrocartilage complex
- B. Correlate gross or histopathologic findings with their appearance on RhUS imaging
- C. Demonstrate sonographic pathologic findings using RhUS imaging

- D. Recognize the utility of RhUS for the following adult and pediatric (where applicable) rheumatic conditions
 - 1. Inflammatory autoimmune arthropathies
 - 2. Crystal-associated arthropathies
 - 3. Mechanical derangements of joints and soft tissue structures
 - 4. Miscellaneous conditions pertaining to the practice of rheumatology, such as Giant Cell Arteritis and Sjogrens syndrome
- E. Recognize the utility of RhUS for injection guidance.
- E. Identify rheumatic diseases for which RhUS findings have been incorporated into ACR/EULAR diagnostic criteria
- F. Integrate RhUS findings within the context of adult and/or pediatric rheumatic disease to inform diagnostic and management decisions

DIAGNOSTIC TESTING

- A. Explain underlying principles and technical considerations of RhUS
 - 1. Discuss basic physics principles underlying the use of ultrasound
 - 2. Utilize knowledge of physics to optimize image acquisition
 - 3. Utilize the appropriate machine settings for the indication of the scan, and adjust accordingly to optimize image acquisition (depth, frequency, focal zones, gain, pulse repetition frequency (PRF))
 - 4. Identify and use the appropriate transducer for the target area to be scanned
 - 5. Identify and describe sonographic artifacts and develop strategies to reduce interference with image acquisition
 - 6. Explain the principle of Doppler (color and power), balance Doppler sensitivity against artifact, and employ Doppler in the diagnosis, treatment and monitoring of rheumatic disease
- B. Discuss the indications and limitations of performing RhUS
- C. Distinguish between the advantages and disadvantages of using RhUS for diagnostic testing

RESEARCH PRINCIPLES

- A. Pose relevant questions and perform a directed literature search
- B. Critically review and interpret the RhUS literature to inform a change in practice
- C. Participate in scholarly activity to advance the field of RhUS

II. PATIENT CARE

COMPONENT 1 – INFORMATION GATHERING and RhUS PROCEDURE

1. Obtain an accurate and relevant clinical history prior to the RhUS examination
2. Review laboratory and diagnostic information relevant to the indication for the procedure
3. Correlate RhUS findings to a relevant physical examination for the target area to be scanned
 - a. Physical exam should include inspection, palpation, passive range and active range of motion against resistance
 - b. Physical exam should include dynamic maneuvers when indicated
4. Perform a standardized complete or directed limited RhUS examination of the target area
 - a. Prepare the examination room to reduce artifact
 - b. Place the patient and machine in the optimum position to obtain quality images, while maintaining the safety and comfort of the patient and provider
 - c. Position the target area to allow examination of the structure of interest
 - d. Place the transducer in the correct position and adjust the transducer to optimize image acquisition (translation, rotation, angulation, pressure, compression, heel-toe, rocking)
 - e. Perform a complete or limited RhUS exam utilizing standardized scan sets when indicated
 - f. Obtain additional views when needed to support interpretation
 - g. Demonstrate pathology in orthogonal planes
 - h. Utilize dynamic scanning when indicated
 - i. Perform contralateral comparison when indicated
5. Interpret RhUS findings within the context of rheumatic disease states
 - a. Integrate RhUS findings with complementary imaging modalities
6. Perform diagnostic arthrocentesis or aspiration of MSK structures with accurate needle placement
 - a. Identify appropriate indications and contra-indications
 - b. Identify appropriate targets
 - c. Ensure critical structures do not reside in the needle path
 - d. Utilize RhUS to mark an area for arthrocentesis via the paperclip or other technique when the indirect visualization method is used
 - e. Use real-time RhUS imaging when the direct visualization method is used

- f. Perform the procedure with aseptic or sterile technique, as appropriate
- g. Record images that adequately document the procedure, which may include pre-procedure, paper clip marker, post-procedure or video imaging, as necessary
7. Appropriately interpret, label and document RhUS findings and procedures and archive images to support the findings
8. Refer patients for additional evaluation or imaging when diagnostic uncertainty remains after the RhUS examination

COMPONENT 2 – SYNTHESIS OF TREATMENT PLAN

1. Integrate RhUS findings with the history, physical, laboratory and other imaging findings to develop and recommend a management plan
2. Suggest additional serologic, imaging or other diagnostic testing based on RhUS findings in order to establish a correct diagnosis

COMPONENT 3 – IMPLEMENTATION OF TREATMENT

1. Accurately place a needle under ultrasound guidance to perform indicated procedures, such as aspiration, injection, or debridement
 - a. See COMPONENT 1: 6 (a-h) above

COMPONENT 4 – REASSESSMENT AND PATIENT FOLLOW-UP

1. Utilize RhUS findings to appropriately monitor disease activity, disease progression and response to treatment

III. PRACTICE-BASED LEARNING AND IMPROVEMENT

A. Independent Learning

1. Seek resources to enhance medical knowledge in RhUS
2. Seek resources to enhance procedural skills in RhUS
3. Use RhUS at the point of care to enhance clinical interactions
4. Build upon a RhUS fund of knowledge by regularly assessing the literature to remain current with novel indications, approaches and findings in RhUS

B. Self-evaluation of performance

1. Actively seek, reflect upon, and develop plans for practice improvement based on feedback from RhUS patients, colleagues and mentors.
2. Compare RhUS findings to alternative imaging findings, such as MRI, when available

C. Incorporation of feedback into improvement of clinical activity (per Core Document)

IV. SYSTEMS-BASED PRACTICE

A. Partners in healthcare delivery

1. Provide rheumatology RhUS imaging services when requested by colleagues within or outside of rheumatology

B. Systems thinking (per Core Document)

C. Advocacy for the patient (per Core Document)

D. Cost-effective health care

1. Appraise the cost of RhUS procedures and balance this with the value added to patient care from the findings
2. Identify the indications and limitations for the use of RhUS and demonstrate sensitivity for the financial costs to the patient and the healthcare system

V. INTERPERSONAL AND COMMUNICATION SKILLS

A. Gathering information (per Core Document)

B. Recognizing and incorporating the patient's perspective

- a. Explain the purpose and finding of the RhUS with relevance to the patient's presentation
- b. Use RhUS as a tool to educate a patient about his/her condition

C. Providing Information

- a. Communicate findings in a timely and comprehensible manner to the referring provider

D. Trust (per Core Document)

VI. PROFESSIONALISM

A. Primacy of patient interest (per Core Document)

B. Physician responsibility and accountability

- a. Provide secure image data storage with back up, which is HIPAA compliant
- b. Maintain ultrasound equipment and identify signs of wear or malfunction
- c. Appropriately clean the unit and probes after each use

C. Humanistic qualities and altruism (per Core Document)

D. Ethical behavior

- d. Seek reimbursement for RhUS only when the clinician managing the case has reason to believe the modality will hold diagnostic or therapeutic benefit to the patient

APPENDIX A. RhUS ENTRUSTABLE PROFESSIONAL ACTIVITY

**A Rheumatology practitioner using RhUS should:
Identify, image and interpret the inflammatory and non-inflammatory
pathology of common rheumatic diseases.**

MK, PC, ICS, P, PBLI, SBP

APPENDIX B. RhUS CURRICULAR MILESTONES

RhUS Curricular Milestones are incorporated within the corresponding Rheumatology Curricular Milestones.

**These milestones are developed for a one year mini-curriculum. The time designations indicate how many months it should take a fellow to acquire each milestone within that framework, assuming that fellows have access to an ultrasound machine for a minimum of 2 hours each week. The number of scans to achieve proficiency will vary by fellows, but may take as few as 50 and up to 300 scans.

PC1-05

1. Gather sufficient history and physical examination data to identify when a RhUS examination is indicated.
 - a. 3 Months: Gather and incorporate pertinent information
2. Correlate relevant physical examination findings of target area to planned RhUS examination
 - a. 3 Months: Utilize physical exam to inform RhUS exam
3. Perform a standardized complete or directed limited RhUS examination
 - a. 3 Months: Prepare exam room and patient position
 - b. 6 Months: Obtain standard image sets for each joint region
 - c. 9 Months: Obtain optimal images for standard scanning sets, additional views and dynamic maneuvers
 - d. 12 Months: Teach others the standard views
4. Interpret RhUS findings within the context of rheumatic disease states
 - a. 6 Months: Identify basic US abnormalities (eg. Synovitis, effusion, erosion)
 - b. 12 Months: Identify complex US abnormalities (eg. Disease specific pathology)

PC4-03

5. Perform diagnostic arthrocentesis or aspiration with accurate needle placement
 - a. 3 Months: Identify appropriate use of RhUS procedures
 - b. 9 Months: Utilize RhUS for direct (real-time) and indirect needle placement of large joints
 - c. 12 Months: Utilize RhUS for direct (real-time) and indirect needle placement of small joints and tendon sheaths, perineural injections and other smaller targets

PC5-04

6. Provide consultative care to assist in diagnosis, management and follow-up
 - a. 9 Months: for routine clinical problems with basic assessment
 - b. 12 Months: for complex clinical problems with detailed assessment

MK2-02

7. Explain underlying principles and technical considerations of RhUS
 - a. 6 Months: Describe the basic physics of ultrasound
 - b. 12 Months: Optimize image acquisition
8. Recognize sonographic artifacts
 - a. 3 Months: Identify artifacts
 - b. 6 Months: Explain the mechanism
 - c. 9 Months: Employ strategies to mitigate or utilize artifacts
9. Appropriately employ Doppler
 - a. 6 Months: Explain the physics
 - b. 9 Months: Employ for diagnosis

MK2-03

10. Analyze the utility of RhUS to assist in the diagnosis and management of rheumatic disease
 - a. 3 Months: Recognize indications and limitations
 - b. 6 Months: Recognize basic pathologic findings
 - c. 9 Months: Recognize disease specific pathology

MK2-04

11. Identify the RhUS appearance of normal musculoskeletal anatomy
 - a. 3 Months: Correlate tissue type and anatomic structures to RhUS appearance
 - b. 9 Months: Identify common anatomical variants

PBLI1-01

12. Seek resources to enhance knowledge and skills in RhUS
 - a. 6 Months: Compare alternative imaging findings, such as MRI and seek mentoring
 - b. 6-12 Months: Assess the medical literature to remain current

SBP3-01

13. Appraise the cost of RhUS and balance this with value added to patient care
 - a. 12 Months: Recognize the time and financial implications of utilizing RhUS to the patient, provider and system

SBP3-02

14. Appraise the unique barriers in cost and credentialing for the use of RhUS
 - a. 6 Months: Recognize
 - b. 12 Months: Identify ways to address and advocate for change

PROF2-01

- 15. Provide for secure and HIPAA compliant image data storage with back-up
 - a. 6 Months: Recognize importance
 - b. 12 Months: Identify and implement a plan
- 16. Perform and seek reimbursement for indicated procedures
 - a. 6-12 Months: Demonstrate fiscal responsibility and accountability
- 17. Maintain clean and functioning ultrasound equipment
 - a. 6 Months: Ensure proper machine function and safety

ICS3-01

- 18. Document and communicate findings to the referring provider
 - a. 6 Months: Identify components of RhUS exam documentation
 - b. 12 Months: Clearly interpret the findings on the basis of context, audience and/or situation

1. Gathers and synthesizes essential and accurate information to define each patient's clinical problems (PC1)					
RhUS Curricular Milestone					
Number	By the listed time the fellow should be able to				For this curricular milestone
	3 months	6 months	9 months	12 months	
PC1-05:1	Gather and Incorporate				Gather history and physical exam data to identify indication for RhUS
	<input type="checkbox"/> <input type="checkbox"/>				
PC1-05:2	Utilize physical exam to inform RhUS exam				Correlate relevant physical exam findings to RhUS exam
	<input type="checkbox"/> <input type="checkbox"/>				
PC1-05:3	Prepare patient and room	Obtain standard images	Obtain optimal images, additional views and dynamic maneuvers	Teach others standard views	Perform standardized complete or directed limited RhUS exam
	<input type="checkbox"/>	<input type="checkbox"/>	<input type="checkbox"/>	<input type="checkbox"/>	
PC1-05:4		Identify basic ultrasound abnormalities		Identify complex ultrasound abnormalities	Interpret RhUS findings within the context of rheumatic disease
		<input type="checkbox"/>	<input type="checkbox"/>	<input type="checkbox"/>	

4. Demonstrates skill in performing and interpreting procedures. (PC4)					
RhUS Curricular Milestone					
Number	By the listed time the fellow should be able to				For this curricular milestone
	3 months	6 months	9 months	12 months	
PC4-03:5	Identify appropriate use		Perform large target direct and indirect needle placement	Perform small target direct and indirect needle placement	Perform diagnostic arthrocentesis with accurate needle placement
	<input type="checkbox"/> <input type="checkbox"/> <input type="checkbox"/> <input type="checkbox"/> <input type="checkbox"/> <input type="checkbox"/>				

5. Request and provide consultative care. (PC5)					
RhUS Curricular Milestone					
Number	By the listed time the fellow should be able to				For this curricular milestone
	3 months	6 months	9 months	12 months	
PC5-04:6			Basic assessment of routine problems	Detailed assessment for complex problems	Provide consultative care to assist in diagnosis, management and follow-up
	<input type="checkbox"/> <input type="checkbox"/> <input type="checkbox"/> <input type="checkbox"/>				

7. Knowledge of diagnostic testing and procedures. (MK2)					
RhUS Curricular Milestone					
Number	By the listed time the fellow should be able to				For this curricular milestone
	3 months	6 months	9 months	12 months	
MK2-02:7		Describe basic ultrasound physics		Optimize image acquisition	Explain the principles and technical considerations of RhUS
	<input type="checkbox"/> <input type="checkbox"/> <input type="checkbox"/> <input type="checkbox"/> <input type="checkbox"/>				
MK2-02:8	Identify artifacts	Explain the mechanism	Employ strategies to mitigate or utilize artifacts		Recognize sonographic artifacts
	<input type="checkbox"/> <input type="checkbox"/> <input type="checkbox"/> <input type="checkbox"/> <input type="checkbox"/> <input type="checkbox"/>				

MK2-02:9		Explain the physics	Employ for diagnosis		Appropriately employ Doppler
		<input type="checkbox"/>	<input type="checkbox"/>	<input type="checkbox"/>	
MK2-03:10	Recognize indications and limitations	Recognize basic pathologic findings	Recognize disease specific pathology		Utilize RhUS to diagnose and manage rheumatic disease
	<input type="checkbox"/>	<input type="checkbox"/>	<input type="checkbox"/>	<input type="checkbox"/>	
MK2-04:11	Correlate tissue and structures to RhUS		Identify common anatomic variants		Identify RhUS appearance of normal anatomy
	<input type="checkbox"/>	<input type="checkbox"/>	<input type="checkbox"/>	<input type="checkbox"/>	

13. Monitors practice with a goal for improvement (PBLI1)					
RhUS Curricular Milestone					
Number	By the listed time the fellow should be able to				For this curricular milestone
	3 months	6 months	9 months	12 months	
PBLI1-01:12		Compare alternative imaging findings and seek mentoring	Assess the medical literature to remain current		Seek resources to enhance knowledge and skills in RhUS
	<input type="checkbox"/>	<input type="checkbox"/>	<input type="checkbox"/>	<input type="checkbox"/>	<input type="checkbox"/>

11. Identifies forces that impact the cost of health care, and advocates for and practices cost-effective care (SBP3)					
RhUS Curricular Milestone					
Number	By the listed time the fellow should be able to				For this curricular milestone
	3 months	6 months	9 months	12 months	
SBP3-01:13				Recognize the time and financial implications of RhUS to the patient, provider and system	Appraise the cost of RhUS and balance with value added to patient care

			<input type="checkbox"/>	<input type="checkbox"/>	
SBP3-02:14		Recognize		Identify ways to address and advocate for change	Appraise the unique barriers in cost and credentialing for RhUS
			<input type="checkbox"/>	<input type="checkbox"/>	

18. Accepts responsibility and follows through on tasks. (PROF 2)					
RhUS Curricular Milestone					
Number	By the listed time the fellow should be able to				For this curricular milestone
	3 months	6 months	9 months	12 months	
PROF 2-01:15		Recognize importance		Identify and implement plan	Provide for secure and HIPAA compliant image data storage with back-up
			<input type="checkbox"/>	<input type="checkbox"/>	<input type="checkbox"/>
PROF 2-01:16		Demonstrate fiscal responsibility and accountability			Perform and see reimbursement for indicated procedures
		<input type="checkbox"/>	<input type="checkbox"/>	<input type="checkbox"/>	<input type="checkbox"/>
PROF 2-01:17		Ensure proper machine function and safety			Maintain clean and functioning ultrasound equipment
		<input type="checkbox"/>	<input type="checkbox"/>	<input type="checkbox"/>	

23. Appropriate utilization and completion of health records (ICS3)					
RhUS Curricular Milestone					
Number	By the listed time the fellow should be able to				For this curricular milestone
	3 months	6 months	9 months	12 months	
ICS3-01:18		Identify components of exam documentation		Interpret findings on basis of context, audience or situation	Document and communicate findings to referring providers
		<input type="checkbox"/>	<input type="checkbox"/>	<input type="checkbox"/>	<input type="checkbox"/>

APPENDIX C. RhUS TOOLBOX: ACTIVITIES AND ASSESSMENTS

Toolbox for Tracking of RhUS Curricular Milestone Implementation

Directions: You may utilize the provided list of activities and assessments and supplement with others that are unique to your program.

Activities for RhUS

Experience	Activity
Clinical experience in mentored setting	Ambulatory Service
	<ul style="list-style-type: none"> • Outpatient clinic <ul style="list-style-type: none"> ○ General rheumatology clinic ○ RhUS Specific Clinic ○ Injection Clinic
	Inpatient rheumatology consult service
	Elective <ul style="list-style-type: none"> • Mentored training by non-rheumatology provider (radiology, PM&R, orthopaedics) • Hands-on RhUS workshops • Web-based RhUS study feedback
Committee participation	Participation on committee <ul style="list-style-type: none"> • Local • Regional • National • International
Didactics	Local <ul style="list-style-type: none"> • Core curriculum conference • Journal club • Assigned reading discussions • Interdisciplinary conferences • Case conference Regional RhUS conferences National or international RhUS conferences
Self-study	Independent readings <ul style="list-style-type: none"> • Textbook • Journal articles

	<ul style="list-style-type: none"> • Internet based research • Internet based study • Web-based modules • Videos <p>Other</p>
Fellow projects and presentations	Presentation by fellow
	<p>Clinical RhUS research project</p> <ul style="list-style-type: none"> • Abstract presentation • Manuscript preparation and submission
	RhUS Quality Improvement project
Simulation	<p>Anatomic model Cadaver lab</p> <ul style="list-style-type: none"> • Dissection • Scanning • Procedural practice <p>Live model scanning</p>

Assessment Tools

Methods	Rheumatology Assessment Tools
Anatomic model	<p>Anatomic model Cadaver lab</p> <ul style="list-style-type: none"> • Scanning • Procedural assessment
Direct observation	Mini-PEX (procedure)
Objective Structured Clinical Exam (OSCE)	<p>Scanning skills Interpretation</p>
Multisource assessment	<ul style="list-style-type: none"> • Self-assessment • Faculty evaluations • Patient evaluations • Procedural competency assessments • RhUS Mini-curriculum milestones
Knowledge testing	<ul style="list-style-type: none"> • Quizzes

	<ul style="list-style-type: none"> • Summative examination (MCQ or essay/fill in the blank)
Practice/billing audit	Medical documentation review
Project assessment by faculty	Quality Improvement project Research project
Review case/procedure log	
Review patient outcomes	
Workshops	Based on certification blueprint

RhUS Curricular Milestones Tables

Subspecialty Reporting Milestone	Rheumatology Curricular Milestone				Your Training Program		
	Number	By This Time (months)	The fellow should be able to	For this curricular milestone	Activities	Assessment Tools	
Knowledge of Diagnostic Testing and Procedures (MK2)	MK2-02:7	6	Describe basic ultrasound physics	Explain the principles and technical considerations of RhUS			
		12	Optimize image acquisition				
	MK2-02:8	3	Identify artifacts	Recognize sonographic artifacts			
		6	Explain the mechanism				
		9	Employ strategies to mitigate or utilize artifacts				
	MK2-02:9	6	Explain the physics	Appropriately employ Doppler			
		9	Employ for diagnosis				
	MK2-03:10	3	Recognize indications and limitations	Utilize RhUS to diagnose and manage rheumatic disease			
		6	Recognize basic pathologic findings				
		9	Recognize disease specific pathology				
	MK2-04:11	3	Correlate tissue and structures to RhUS	Identify RhUS appearance of normal anatomy			
		9	Identify common anatomic variants				
	Gathers And Synthesizes Essential And Accurate Information To Define Each Patient's Clinical	PC1-05:1	3	Gather and Incorporate	Gather history and physical exam data to identify indication for RhUS		
		PC1-05:2	3	Utilize physical exam to inform RhUS exam	Correlate relevant physical exam findings to RhUS exam		

Problems (PC1)	PC1-05:3	3	Prepare patient and room	Perform standardized complete or directed limited RhUS exam		
		6	Obtain standard images			
		9	Obtain optimal images, additional views and dynamic maneuvers			
		12	Teach others standard views			
	PC1-05:4	6	Identify basic ultrasound abnormalities	Interpret RhUS findings within the context of rheumatic disease		
		12	Identify complex ultrasound abnormalities			
Demonstrates skill in performing and interpreting procedures (PC4)	PC4-03:5	3	Identify appropriate use	Perform diagnostic arthrocentesis of MSK structures with accurate needle placement		
		9	Perform large target direct and indirect needle placement			
		12	Perform small target direct and indirect needle placement			
Request and provide consultative care (PC5)	PC4-04:6	9	Basic assessment of routine problems	Provide consultative care to assist in diagnosis, management and follow-up		
		12	Detailed assessment for complex problems			
Monitors practice with a goal for improvement (PBLI1)	PBLI1-01:12	6	Compare alternative imaging findings and seek mentoring	Seek resources to enhance knowledge and skills in RhUS		
		9-12	Assess the medical literature to remain current			
Identifies forces that impact the cost of health care, and advocates for	SBP3-01:13	12	Recognize the time and financial implications of RhUS to the patient, provider and system	Appraise the cost of RhUS and balance with value added to patient care		

and practices cost-effective care (SBP3)	SBP3-02:14	6	Recognize	Appraise the unique barriers in cost and credentialing for RhUS		
		12	Identify ways to address and advocate for change			
Accepts responsibility and follows through on tasks (PROF 2)	PROF 2-01:15	6	Recognize importance	Provide for secure and HIPAA compliant image data storage with back-up		
		12	Identify and implement plan			
	PROF 2-01:16	6-12	Demonstrate fiscal responsibility and accountability	Perform and seek reimbursement for indicated procedures		
	PROF 2-01:17	6	Ensure proper machine function and safety	Maintain clean and functioning ultrasound equipment		
Appropriate utilization and completion of health records (ICS3)	ICS3-01:18	6	Identify components of exam documentation	Document and communicate findings to referring providers		
		12	Interpret findings on basis of context, audience or situation			

APPENDIX D. PEDIATRIC RHEUMATOLOGY SUPPLEMENT

Pediatric Specific MSUS Anatomy

- a) General:
 - i) Growth Plates (including presence of normal/physiologic Doppler signal)
 - ii) Cartilage/ non-ossified bone (including vascular channels/Doppler)
 - (1) Identify and utilize the synovial reflection to distinguish between cartilage and the joint space.
 - (2) Utilize compression maneuvers to distinguish between cartilage and the joint space.
 - (3) Identify bony contours and landmarks that represent non-ossified bone
 - (4) Utilize dynamic maneuvers to clarify structures
 - iii) Secondary ossification centers
 - iv) Normal Doppler activity
 - (1) Distinguish between intra-articular vs intra-synovial Doppler signal
 - b) Joint specific
 - i) Ankle: subtalar joint, talonavicular joint
 - ii) Knee: medial and lateral parapatellar views
- 1) Basic Regional Pathology (** = advanced pathology)
- a. General
 - i. Effusion
 - ii. Synovial hypertrophy
 - iii. Erosion
 - iv. Tenosynovitis
 - v. Enthesitis
 - vi. Paratenonitis
 - vii. Pathologic Doppler signal
 - b. Ankle
 - i. Effusion, synovial hypertrophy, synovitis: talonavicular and subtalar joints
 - ii. Enthesitis/apophysitis: Achilles, peroneus brevis, and posterior tibial tendons; plantar fascia
 - iii. Tenosynovitis: peroneal, posterior tibial, flexor hallucis longus, flexor digitorum longus, and extensor compartment tendons
 - iv. Retrocalcaneal bursitis
 - v. Accessory bones due to failure of secondary ossification centers fusing with the navicular (os navicularis) or cuboid (os peroneum) bones**
 - c. Knee

- i. Enthesitis/apophysitis: quadriceps tendons; patellar ligament; (Osgood-Schlatter disease, Sinding-Larsen-Johansson disease) iliotibial band; pes anserine tendons
 - ii. Baker's cyst
 - iii. Deep infrapatellar bursitis
 - d. Wrist
 - i. Ganglion cyst
 - ii. Rheumatoid nodule
 - e. Foot
 - i. Rheumatoid nodule
 - ii. Plantar fasciitis**
 - f. Elbow
 - i. Olecranon bursitis
 - ii. Subluxing ulnar nerve**
- 2) Required Scans (static and dynamic) in addition to required scans in standard adult views:
- a. Ankle: subtalar joint (anterior, medial, lateral, and posterior views), talonavicular joint, extensor tendons
 - b. Knee: parapatellar recesses (medial and lateral)
- 3) Additional Scans for regional pathology
- a. Knee: orthogonal views of posterior when evaluation for Baker cyst

Suggested Reading

- PMID: 15293300 Grechenig W, Mayr JM, Peicha G, et al. Sonoanatomy of the Achilles Tendon Insertion in Children. *J Clin Ultrasound* 2004; 32(7):338-342.
- PMID: 19411390 Rooney ME, McAllister C, Burns JFT. Ankle Disease in Juvenile Idiopathic Arthritis: Ultrasound Findings in Clinically Swollen Ankles. *J Rheum* 2009;36:1725-1729.
- PMID: 10207436 Robben SGF, Lequin MH, Diepstraten AFM, et al. Anterior Joint Capsule of the Normal Hip and in Children with Transient Synovitis: US Study with Anatomic and Histologic Correlation. *Radiology* 1999; 210:499– 507.
- PMID: 21523581 Martinoli C, Valle M, Malattia C, et al. Paediatric musculoskeletal US beyond the hip joint. *Pediatric Radiology* 2011; 41:S113–S124.
- PMID: 17415601 Karmazyn B, Bowyer SL, Schmidt KM, et al. US findings of metacarpophalangeal joints in children with idiopathic juvenile arthritis. *Pediatric Radiology* 2007;37:475–482
- PMID: 21571471 Martinoli C, Garello I, Marchetti A, et al. Hip Ultrasound. *European Journal of Radiology* 2012; 81:3824-31.

- PMID: 26815641 Lanni S, Bovis F, Ravelli A, et al. Delineating the Application of Ultrasound in Detecting Synovial Abnormalities of the Subtalar Joint in Juvenile Idiopathic Arthritis. *Arthritis Care Res* 2016;68:1346-1353.
- PMID: 29437586 Magni-Manzon S et al. Comparison of clinical versus ultrasound determined synovitis in juvenile idiopathic arthritis. *Arthritis Rheum* 2009; 61: 1497-1504.
- PMID: 29437586 De Lucia O, Ravagnani V, Pregolato F, et al. Baseline ultrasound examination as possible predictor of relapse in patients affected by juvenile idiopathic arthritis (JIA). *Ann Rheum Dis* 2018;77:1426-1431.
- PMID 23620551 Collado P, Naredo E, Calvo C, et al. Reduced joint assessment versus comprehensive assessment for ultrasound detection of synovitis in juvenile idiopathic arthritis. *Rheumatology* 2013;52:1477-84.
- PMID: 21921099 Janow GL, Panghaal V, Trinh A, et al. Detection of active disease in juvenile idiopathic arthritis: Sensitivity and specificity of the physical examination vs ultrasound. *J Rheum* 2011;38:261-74.
- PMID 25047864 Roth J, Jousse-Joulin S, Magni-Manzoni S, et al. Definitions for the sonographic features of joints in healthy children. *Arthritis Care Res.* 2015;67:136-42.
- PMID 27234966 Magni-Manzoni S. *Pediatr Rheumatol Online J* 2016;14:33.
- PMID 23143082 Lanni S, Wood M, Ravelli A; Towards a role of ultrasound in children with juvenile idiopathic arthritis. *Rheumatology* 2013;52:413-20
- No PMID Oberle E. Musculoskeletal ultrasound for diagnosis *Current Treatment Options in Rheumatology* 2017;3:49-62 <http://rdcu.be/oW1Y>

APPENDIX E: STANDARD JOINT SCANNING PROTOCOLS

The following scanning protocols are to be utilized by program directors to facilitate RhUS teaching. They have been developed over time by RhUS educators and have subsequently been vetted by consensus methodology among academic and private practice rheumatology sonographers. Scanning protocols are listed by joint area and include the patient position, the target structures and goals for the scan during the initial stages of training. We do not include scanning of non-articular structures, nor designate what is considered a complete or limited examination.

Assumptions:

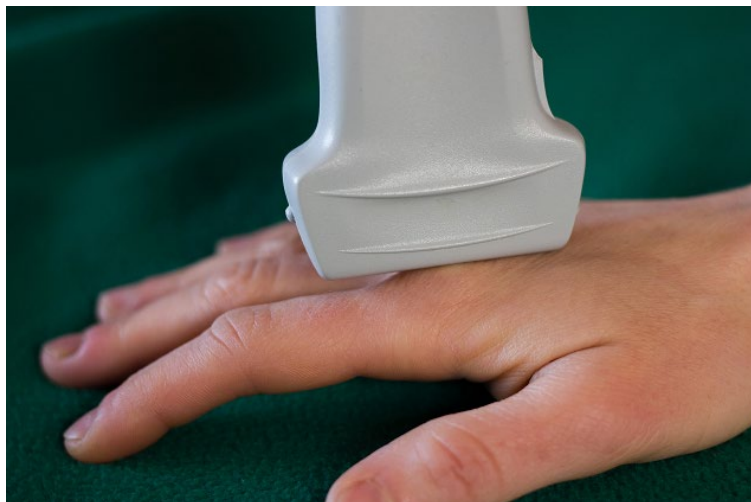- Conventional orientation: left side of screen is proximal in longitudinal views, medial (ulnar) in transverse, unless otherwise labeled
- Depth of field is adequate for most images (at least 50% of screen is filled w/image)
- Patient positioned appropriately
- Doppler is employed appropriately and accurately

Hand/Finger

Dorsal Longitudinal MCP Joint

Position:

- Selected MCP joint in extended position with metacarpal and proximal phalanx in alignment and transducer longitudinal to finger



Structures Identified:

- Metacarpal head
- Phalanx
- Joint cleft with dorsal plate/articular fat

- Extensor tendon
- Metacarpal neck

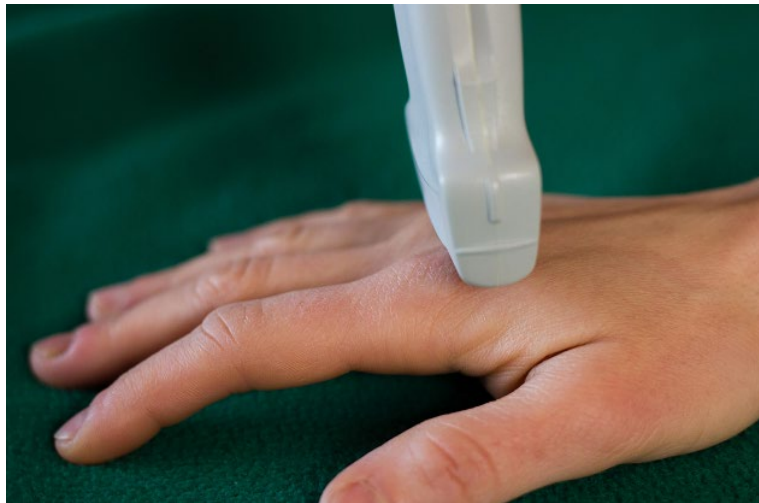Goals for Scan:

- Metacarpal head and proximal portion of proximal phalanx have definable periosteal border
- Soft tissue structures can be distinguished (capsular structures or extensor tendon)

Dorsal Transverse MCP Joint

Position:

- Selected MCP joint in extended position with metacarpal and proximal phalanx in alignment and transducer transverse to finger



Structures Identified:

- Metacarpal
- Extensor tendon
- Digital artery

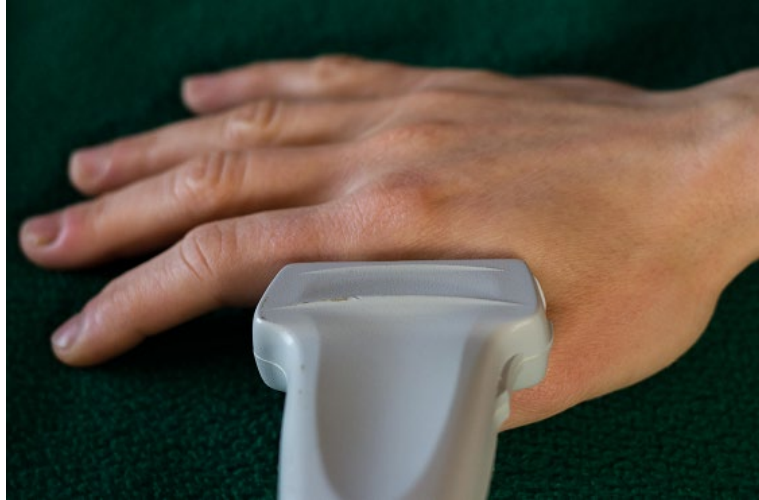Goals for Scan:

- Metacarpal head and proximal phalanx have definable periosteal borders
- Extensor tendons visible with minimal anisotropy

Medial and Lateral Longitudinal MCP Joint

Position:

- MCP joint in extended position with metacarpal and proximal phalanx in alignment and transducer longitudinal to 2nd finger (lateral) or 5th finger (medial)



Structures Identified:

- Metacarpal
- Phalanx
- Collateral ligament

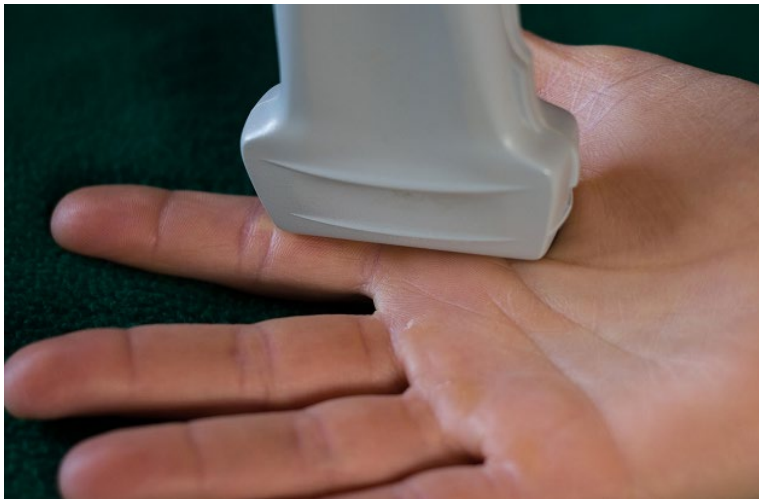Goals for Scan:

- Metacarpal head and proximal phalanx have definable periosteal borders
- Capsular structures or ligament are visible

Volar Longitudinal MCP Joint

Position:

- Selected MCP joint in extended position with metacarpal and proximal phalanx in alignment and transducer longitudinal to finger



Structures Identified:

- Metacarpal head
- Phalanx

- Volar plate/articular fat
- Flexor tendon
- Articular cartilage
- Synovial capsule

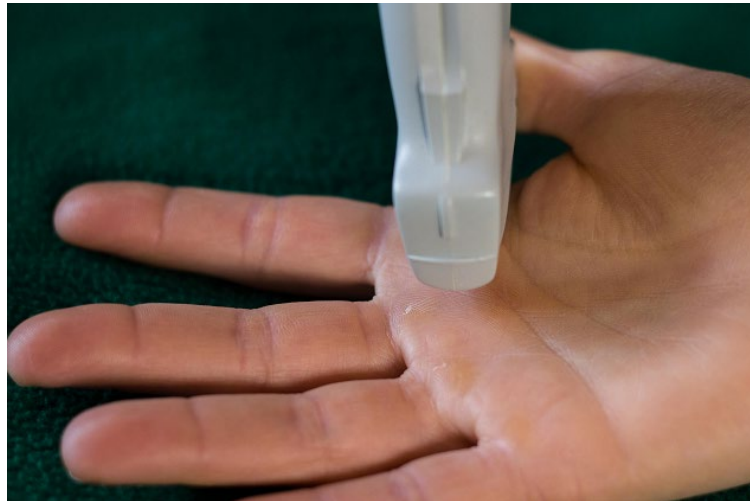Goals for Scan:

- Metacarpal head and proximal phalanx are visible
- MCP synovial reflection visible
- Flexor tendon visible

Volar Transverse 2nd MCP Joint

Position:

- Selected MCP joint in extended position with metacarpal and proximal phalanx in alignment and transducer transverse to finger



Structures Identified:

- Metacarpal
- Flexor tendon
- Articular cartilage

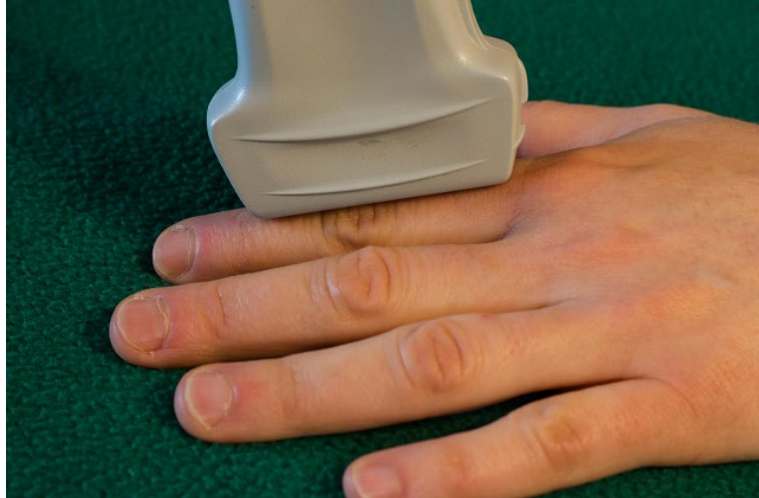Goals for Scan:

- Metacarpal cartilage is visible
- Flexor tendon is defined over the metacarpal

Dorsal Longitudinal PIP Joint

Position:

- PIP in extension with transducer longitudinal to finger



Structures Identified:

- Proximal phalanx
- Middle phalanx
- Extensor tendon
- Joint capsule

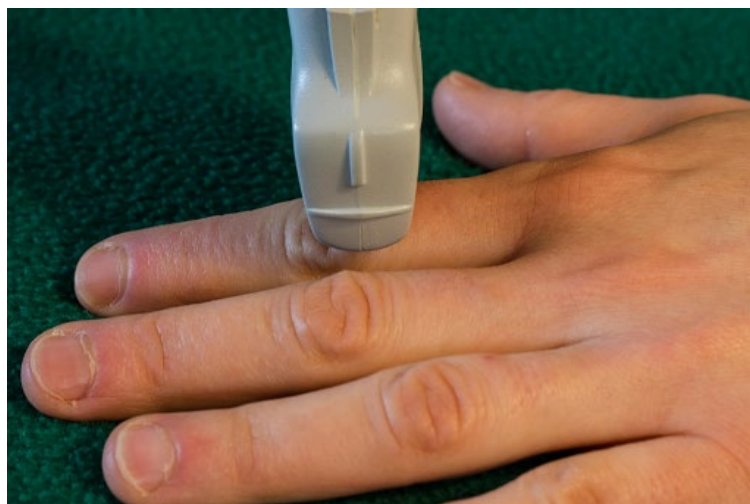Goals for Scan:

- Proximal phalanx and middle phalanx are visible
- PIP synovial reflection is visible
- Extensor tendon is visible

Dorsal Transverse PIP Joint

Position:

- PIP in extension with transducer transverse to finger



Structures Identified:

- Proximal phalanx

- Middle phalanx
- Extensor tendon

Goals for Scan:

- Extensor tendon is visible over the proximal phalanx without anisotropy

Volar Longitudinal PIP Joint

Position:

- PIP in extension with transducer longitudinal to finger



Structures Identified:

- Proximal phalanx
- Middle phalanx
- Flexor tendon

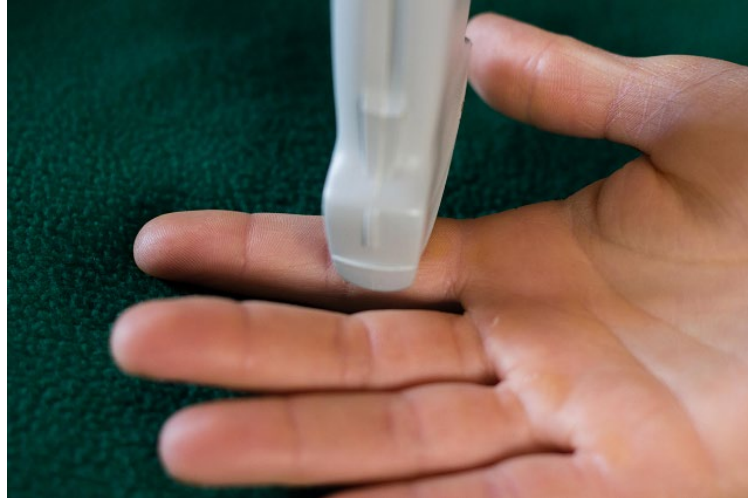Goals for Scan:

- Proximal phalanx and middle phalanx are visible
- PIP synovial reflection is visible
- Flexor tendon is visible

Volar Transverse PIP Joint

Position:

- PIP in extension with transducer transverse to finger



Structures Identified:

- Proximal phalanx
- Middle phalanx
- Flexor tendon

Goals for Scan:

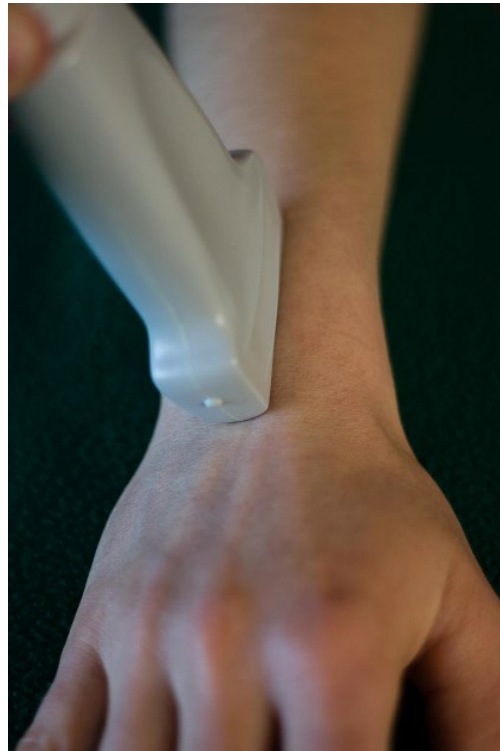- Proximal phalanx cartilage is visible
- Flexor tendon is visible over the proximal phalanx without anisotropy

Wrist

Dorsal Longitudinal Midline

Position:

- Wrist in neutral position with transducer longitudinal to the radius showing the radius, lunate, capitate and 4th extensor tendon compartment, sweeping from radius to ulna



Structures Identified:

- Radius
- Lunate
- Scaphoid
- Capitate
- Extensor tendon
- Joint plates/fat
- Synovial reflection of radiocarpal and intercarpal joints
- Extensor retinaculum

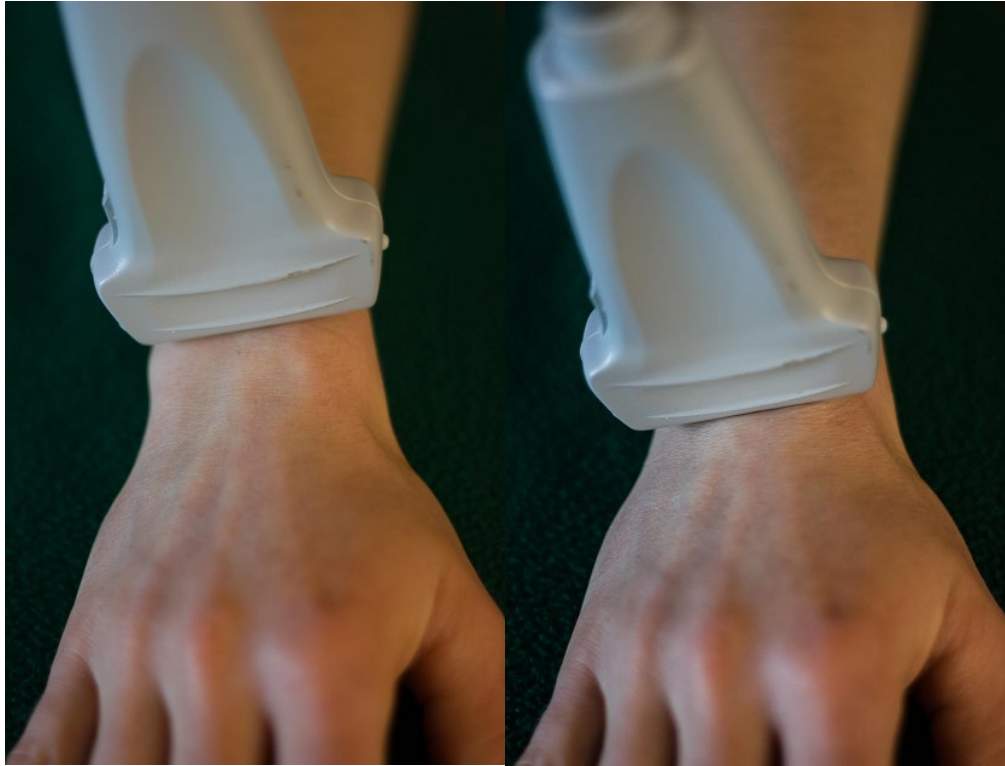
Goals for Scan:

- Distal radius, lunate, and capitate have defined periosteal border
- Extensor tendon continuously visible (from distal radius to mid capitate)

Dorsal Transverse (Proximal and Distal views)

Position:

- Wrist in neutral position with transducer transverse to the wrist joint showing Lister's tubercle and the radio-ulnar joint, sweeping distally to capitate



Structures Identified:

- Proximal View
 - Radius
 - Lister's tubercle
 - Ulna
 - Radio-ulnar joint
 - Extensor carpi radialis longus
 - Extensor carpi radialis brevis
 - Extensor pollicis longus
 - Extensor digitorum and indicis
 - Extensor digiti minimi
- Distal View
 - Scaphoid
 - Lunate
 - Scapho-lunate ligament
 - Common extensor tendons

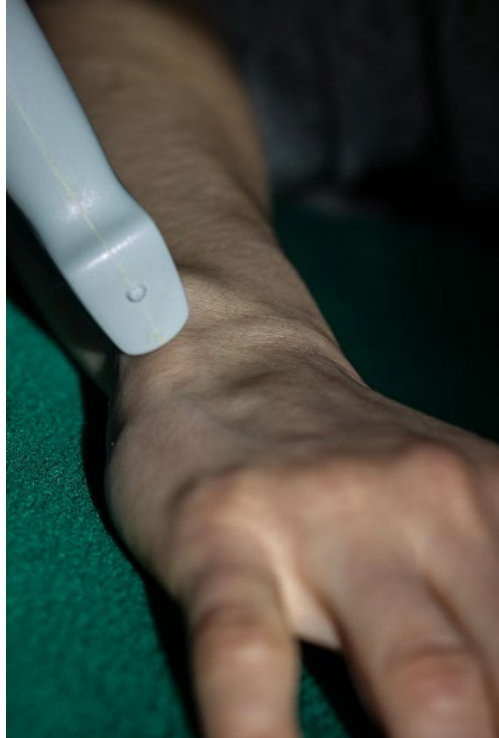
Goals for Scan:

- Radius, ulna, and Lister's tubercle have defined periosteal borders
- Scapholunate interval has defined periosteal borders
- Extensor tendons visible with minimal anisotropy

Medial (Ulnar) Longitudinal

Position:

- Wrist in neutral position with transducer longitudinal to the ulna (anatomic medial), may need to radially deviate wrist to eliminate tendon anisotropy



Structures Identified:

- Ulna
- Lunate
- Triquetrum
- Triangular fibrocartilage
- Extensor carpi ulnaris

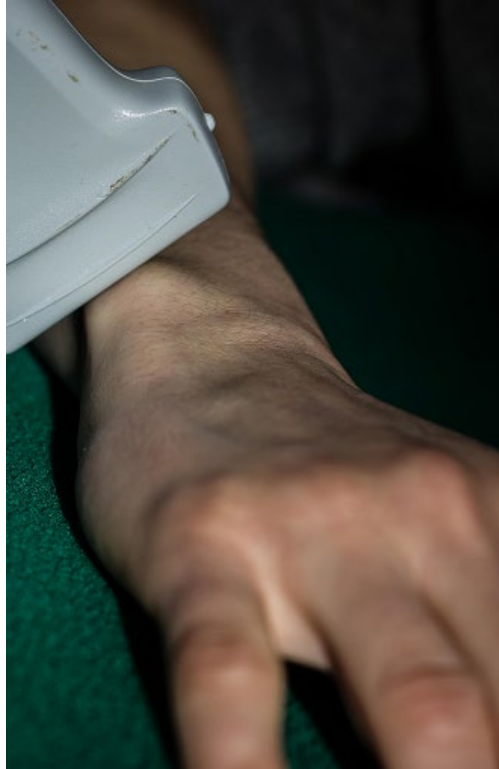Goals for Scan:

- Ulna and triquetrum have defined periosteal borders
- Extensor carpi ulnaris tendon is visible continuously over 75% of the field

Medial (Ulnar) Transverse

Position:

- Wrist in neutral position with transducer transverse to the ulna (anatomic medial)



Structures Identified:

- Ulna
- Extensor carpi ulnaris
- Extensor retinaculum

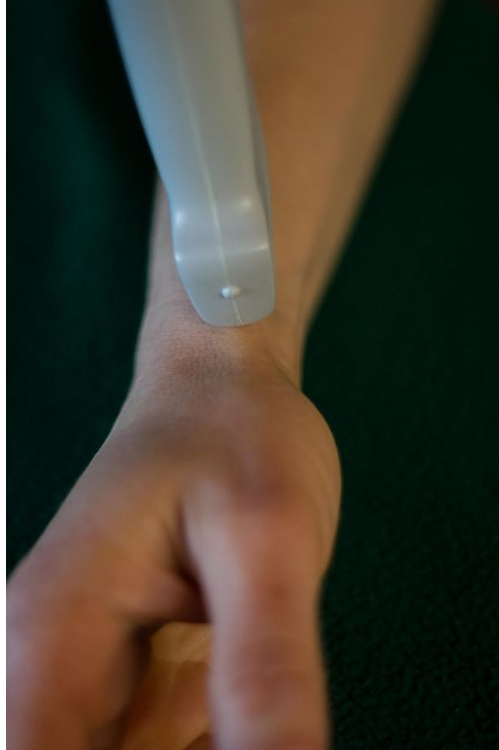
Goals for Scan:

- Ulna has a defined periosteal border
- Extensor carpi ulnaris tendon is visible with minimal anisotropy

Lateral (Radial) Longitudinal

Position:

- Wrist in neutral position with transducer longitudinal to the radius (anatomic lateral), may need slight flexion or extension to bring tendon into view



Structures Identified:

- Radius
- Compartment 1 tendons (extensor pollicis brevis and abductor pollicis longus)

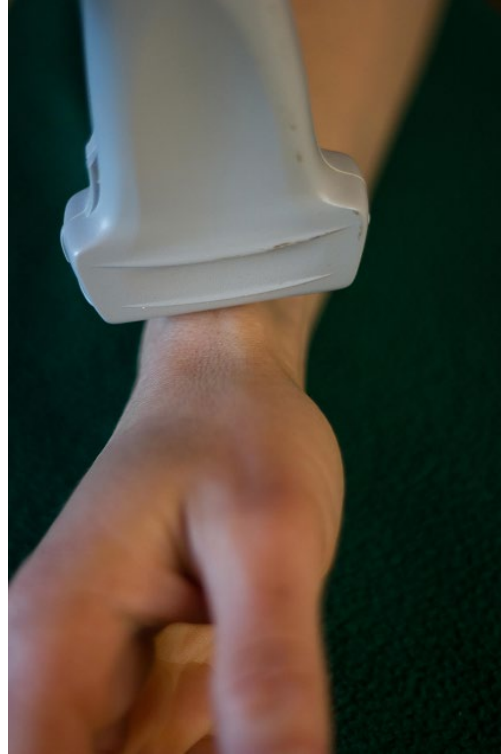Goals for Scan:

- 1st compartment tendons are visible at the distal radial styloid and continuously over 75% of the field
- Radius has defined periosteal borders

Lateral (Radial) Transverse

Position:

- Wrist in neutral position with transducer transverse to the radius (anatomic lateral), may need slight flexion or extension to bring tendon into view



Structures Identified:

- Radius
- Compartment 1 tendons (extensor pollicis brevis and abductor pollicis longus)
- Extensor retinaculum

Goals for Scan:

- 1st compartment tendons are shown with minimal anisotropy
- Extensor retinaculum is visible

Volar Transverse

Position:

- Wrist in neutral position with transducer positioned transverse to the wrist joint with the at the level of the scaphoid and pisiform bones



Structures Identified:

- Pisiform
- Scaphoid tuberosity
- Lunate
- Median nerve
- Flexor tendon
- Ulnar artery
- Ulnar nerve
- Flexor carpi radialis
- Flexor retinaculum

Goals for Scan:

- Periosteal interface of pisiform and scaphoid tuberosity are defined
- Tendons are viewed with minimal anisotropy
- The median nerve is clearly defined and measurable

Volar Longitudinal:

Position:

- Wrist in neutral position with transducer positioned longitudinal to the radius



Structures Identified:

- Radius
- Lunate
- Capitate
- Median nerve
- Flexor tendon

Goals for Scan:

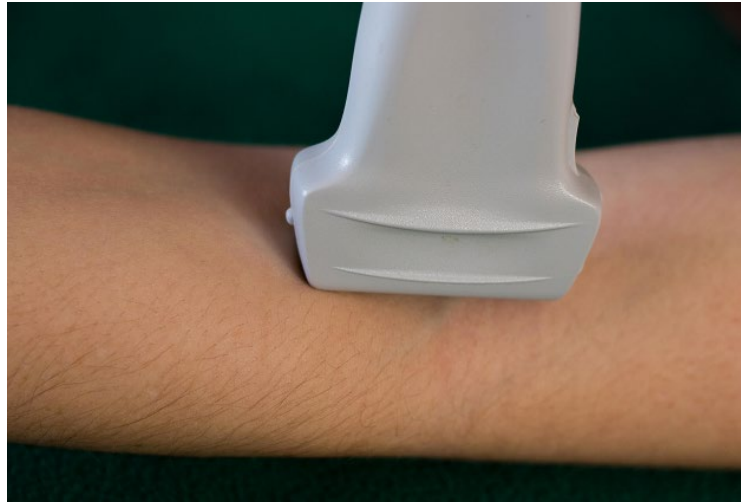- Median nerve is shown continuously over 75% of the field
- The radius, lunate and capitate have defined periosteal borders
- The synovial reflection of the radiocarpal and intercarpal joints can be seen

Elbow

Anterior Humeroradial Longitudinal

Position:

- Elbow in extension with transducer longitudinal to the humerus and spanning the humeral radial joint and including the proximal recess



Structures Identified:

- Capitulum
- Radial head
- Joint pad/fibrocartilage
- Articular cartilage

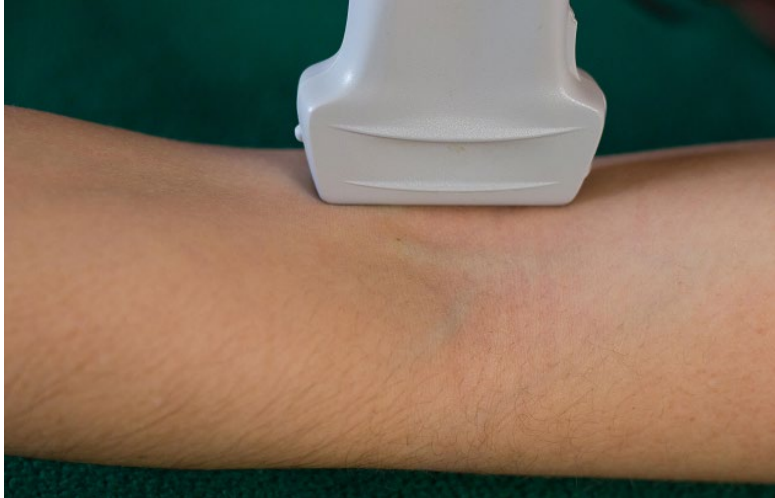Goals For Scan:

- Humerus and radius have defined periosteal borders
- Cartilage and proximal recess well defined

Anterior Humeroulnar Longitudinal

Position:

- Elbow in extension with transducer longitudinal to the humerus and spanning the humeral ulnar joint and including the proximal recess



Structures Identified:

- Trochlea
- Coronoid process
- Joint pad/fibrocartilage
- Articular cartilage
- Brachialis muscle

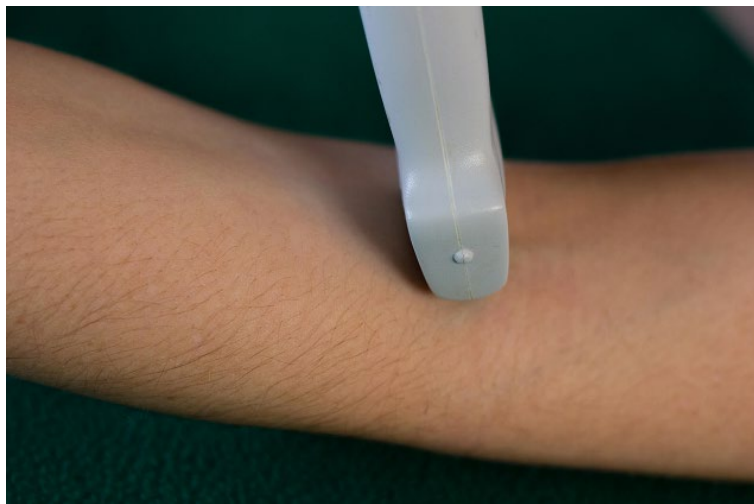
Goals For Scan:

- Humerus and ulna have defined periosteal borders
- Cartilage and proximal recess is well defined.

Anterior Transverse

Position:

- Elbow in extension with transducer transverse to the humerus, including the humeral radial and humeral ulnar joints and proximal recess



Structures Identified:

- Humerus
- Joint capsule
- Articular cartilage

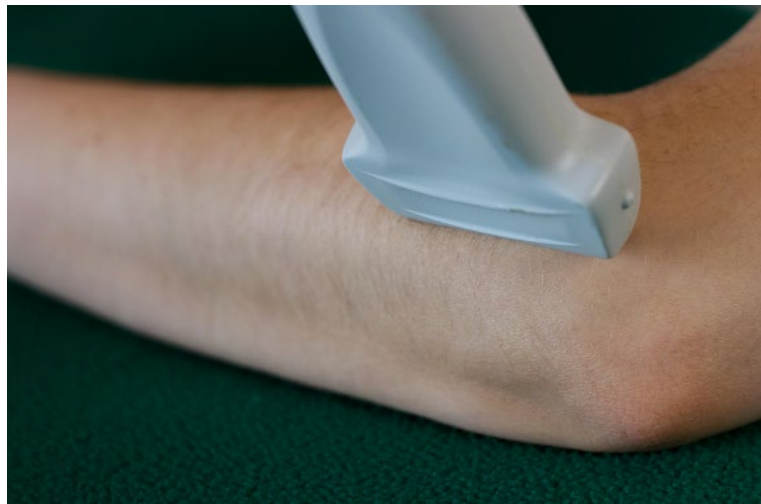Goals for Scan:

- Humerus has defined periosteal borders
- Joint space is clearly seen.

Lateral Longitudinal

Position:

- Elbow in flexed position with transducer anchored on lateral epicondyle in line with common extensor tendon of forearm



Structures Identified:

- Lateral epicondyle
- Extensor tendon origin
- Radial head

Goals for Scan:

- Lateral epicondyle and radial head have defined periosteal borders
- Conjoined extensor tendon shows minimal anisotropy

Medial Longitudinal

Position:

- Elbow in extended position with transducer anchored on medial epicondyle in line with common flexor tendon of forearm



Structures Identified:

- Medial epicondyle
- Flexor tendon origin
- Ulna

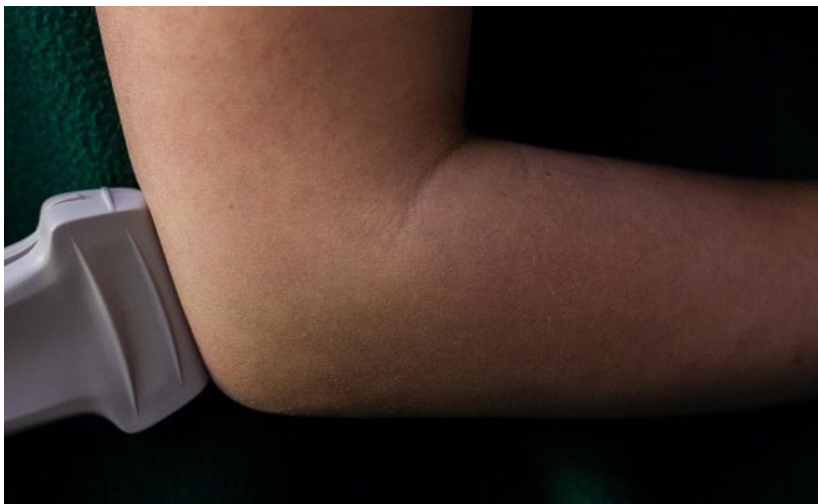Goals for Scan:

- Medial epicondyle has defined periosteal borders
- Flexor tendons shown minimal anisotropy and extend at least 1cm from the bone insertion

Posterior Longitudinal

Position:

- Elbow In 90⁰ flexion, distal transducer on olecranon and sweeping medially to laterally



Structures Identified:

- Triceps tendon

- Olecranon process
- Olecranon fossa
- Joint cleft
- Fat pad

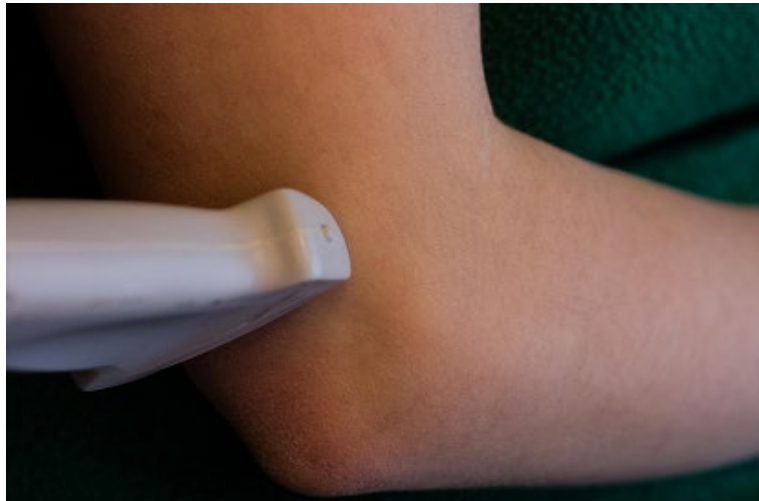Goals for Scan:

- Olecranon tip and humerus have well defined periosteal border
- Triceps tendon shows minimal anisotropy
- Olecranon fossa and joint visualized

Posterior Transverse

Position:

- Elbow In 90⁰ flexion, sweeping from olecranon process to proximal edge of olecranon fossa including the triceps entheses



Structures Identified:

- Olecranon fossa
- Fat pad
- Triceps tendon

Goals for Scan:

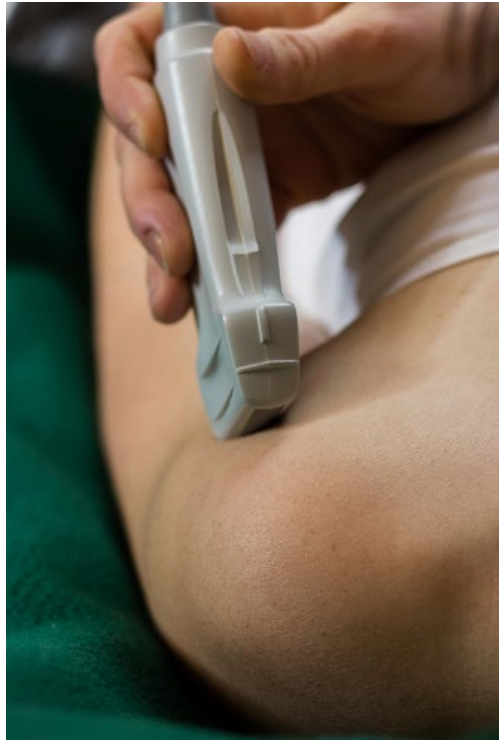- Olecranon fossa shows defined periosteal borders
- Triceps tendon shows minimal anisotropy

Shoulder

Anterior Longitudinal:

Position:

- Shoulder in neutral position with elbow flexed at 90⁰ and palm up (supine) and transducer is longitudinal to the humerus



Structures Identified:

- Biceps tendon
- Humerus
- Deltoid muscle

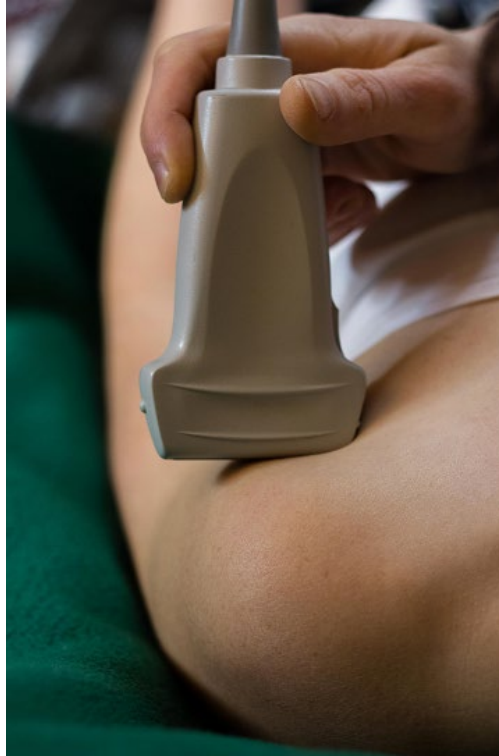Goals for Scan:

- Humerus has a defined periosteal border
- Biceps tendon is fully visible, without anisotropic artifact

Anterior Transverse

Position:

- Shoulder in neutral position (just lateral to the thigh) with elbow flexed at 90⁰ and palm up (supine) and transducer is transverse to the humerus



Structures Identified:

- Biceps tendon
- Humerus
- Deltoid muscle
- Transverse ligament
- Greater tuberosity
- Lesser tuberosity

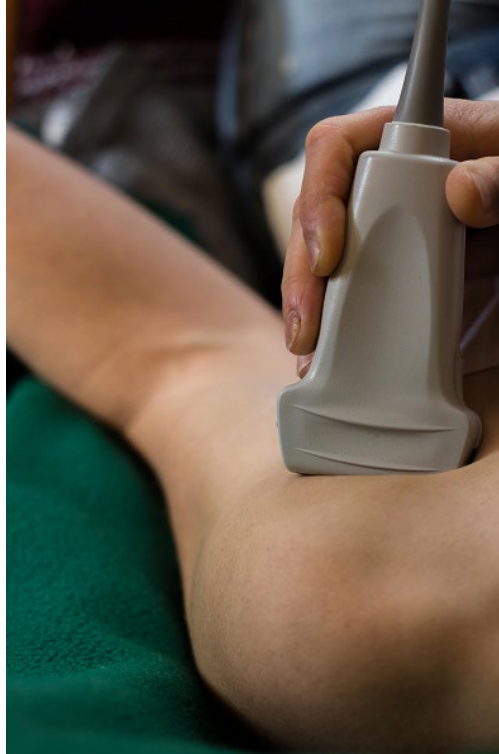Goals for Scan:

- Greater and lesser tuberosities and bicipital groove have defined periosteal borders
- Biceps tendon is visible with minimal anisotropy

Anterior External Rotation (Medial) Longitudinal (to subscapularis)

Position:

- Shoulder in external rotation, elbow at the side and flexed 90⁰ with palm up (supine), and transducer is longitudinal to the subscapularis tendon



Structures Identified:

- Subscapularis tendon
- Humerus
- Coracoid process
- Deltoid
- Subdeltoid bursa

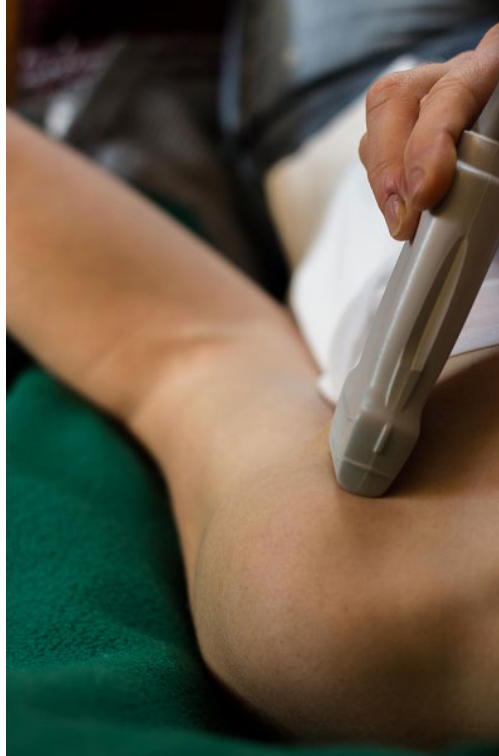Goals for Scan:

- Fibers of subscapularis shown to insert on medial tuberosity
- Medial tuberosity has defined periosteal borders

Anterior External Rotation (Medial) Transverse (to subscapularis)

Position:

- Shoulder in external rotation, elbow at the side and flexed 90⁰ with palm up (supine), and transducer is transverse to the subscapularis tendon



Structures Identified:

- Subscapularis tendon
- Humerus
- Deltoid
- Subdeltoid bursa

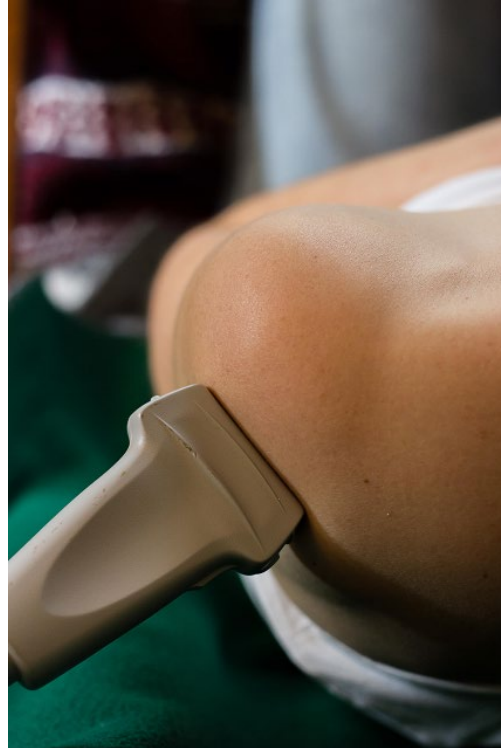Goals for Scan:

- Multipennate structure of subscapularis is well demonstrated without anisotropy
- Medial tuberosity is well defined

Posterior Internal Rotation (Lateral) Longitudinal (tendon view)

Position:

- Shoulder in internal rotation with elbow flexed and hand in lap or reaching to opposite shoulder with transducer longitudinal to the scapular spine and infraspinatus tendon on the lateral shoulder



Structures Identified:

- Infraspinatus tendon
- Humerus
- Deltoid

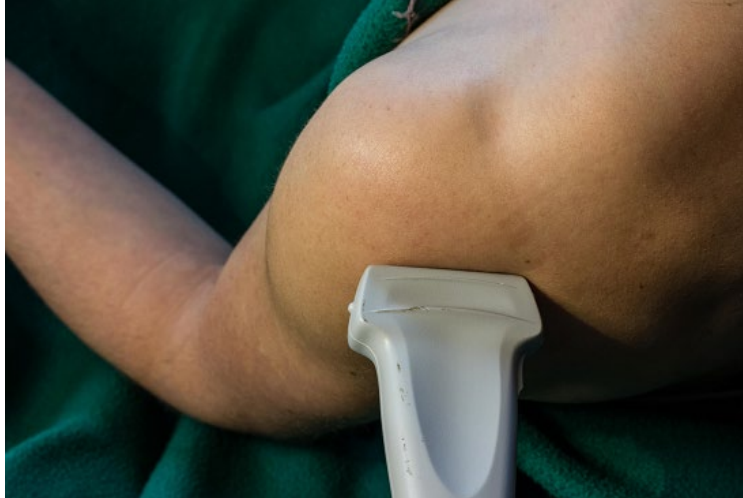Goals for Scan:

- Humeral head has defined periosteal borders
- Infraspinatus tendon insertion is visible including the insertion with minimal anisotropy

Posterior External Rotation Longitudinal (joint view)

Position:

- Shoulder in external rotation at the side and flexed 90° with transducer longitudinal to the scapular spine and infraspinatus tendon



Structures Identified:

- Infraspinatus tendon
- Humerus
- Glenoid
- Posterior labrum
- Deltoid

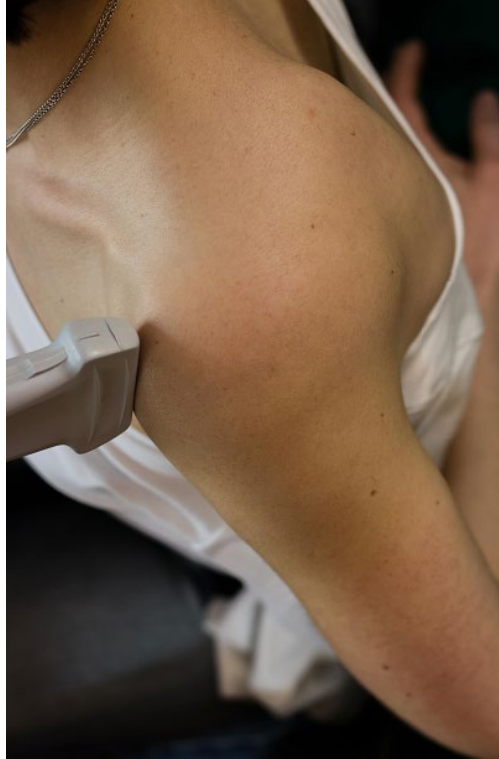Goals for Scan:

- Humeral head and glenoid have defined periosteal borders
- Labrum and infraspinatus are visualized adequately
- Joint recess is properly centered on image

Longitudinal in Cross Position:

Position:

- Shoulder internally rotated with elbow flexed and hand behind the back (maximum internal rotation in extension) and transducer longitudinal to the supraspinatus tendon



Structures Identified:

- Supraspinatus tendon
- Humerus/greater tuberosity
- Subacromial/subdeltoid bursa
- Deltoid

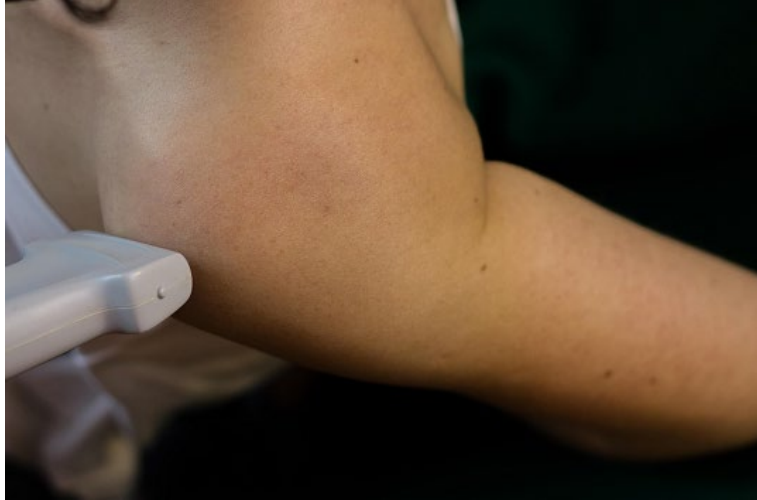Goals for Scan:

- Humerus and greater tuberosity have defined periosteal borders
- Supraspinatus tendon is visible including the insertion with minimal anisotropy
- Subacromial bursa interface is visible

Transverse in Modified Crass Position

Position:

- Shoulder internally rotated with elbow flexed and hand in the back pocket (some internal rotation in extension) and transducer transverse to the supraspinatus tendon



Structures Identified:

- Supraspinatus tendon
- Humerus
- Subacromial bursa
- Deltoid
- Biceps tendon

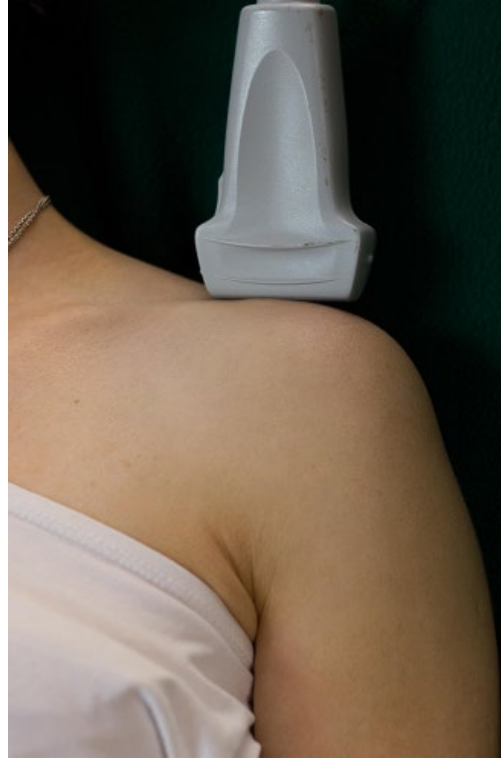Goals for Scan:

- Humerus has defined periosteal borders
- Supraspinatus tendon is visible with minimal anisotropy
- Biceps tendon visible as reference point in left lower corner of image

Superior Longitudinal Acromio-Clavicular Joint

Position:

- Shoulder in neutral position with transducer longitudinal to the clavicle



Structures Identified:

- Acromion
- Clavicle
- Joint capsule

Goals for Scan:

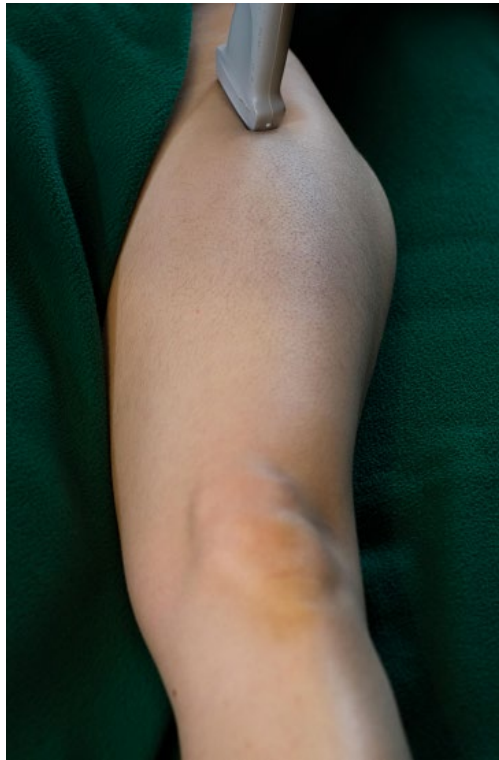- Bone surface of acromion and clavicle have well defined borders
- Synovial capsule shown with minimal anisotropy

Hip

Anterior Longitudinal

Position:

- Hip is in neutral position (normal extension) with 15° external rotation, heels approximated with transducer over hip joint and aligned longitudinally along neck of femur.



Structures Identified:

- Femoral head
- Femoral neck
- Acetabulum
- Anterior labrum
- Joint recess
- Joint capsule

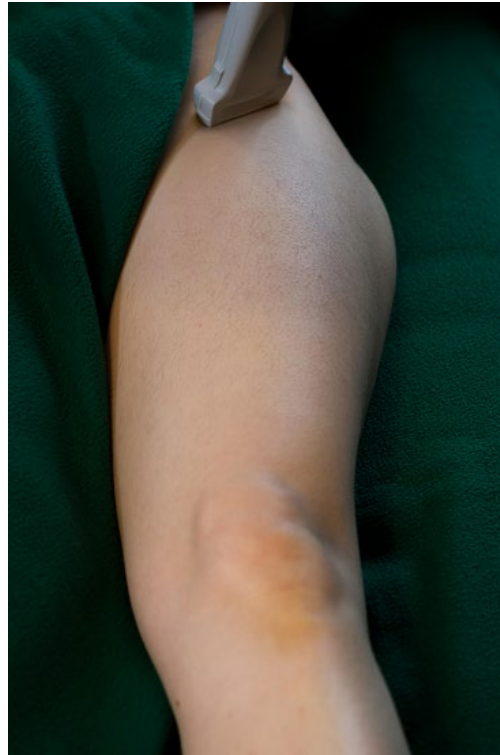Goals for Scan:

- Acetabulum, labrum, femoral head and neck have defined periosteal borders
- Joint capsule is visualized and measured
- Needle trajectory marking accurate, Doppler checked and avoided

Anterior Transverse

Position:

- Hip is in neutral position (normal extension) with 15° external rotation, heels approximated with transducer parallel to the inguinal ligament, sweeping from ilium to trochanter



Structures Identified:

- Femoral head
- Joint capsule
- Iliopsoas
- Femoral artery

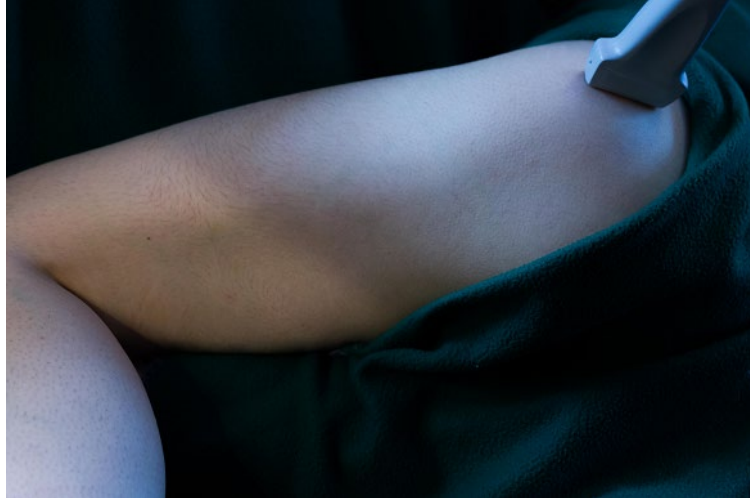Goals for Scan:

- Femoral head has defined periosteal border
- Joint capsule and iliopsoas are visualized

Lateral Longitudinal

Position:

- Hip in neutral position (normal extension) with transducer longitudinal to the femur at the level of the greater trochanter



Structures Identified:

- Gluteus medius tendon
- Gluteus maximus tendon
- Greater trochanter

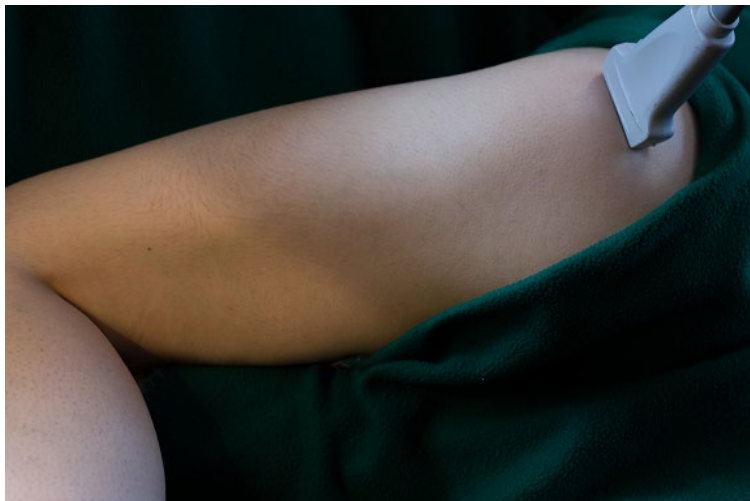Goals for Scan:

- Greater trochanter has defined periosteal border
- Gluteus medius tendon is visualized

Lateral Transverse

Position:

- Hip in neutral position (normal extension) with transducer transverse to femur with anterior and posterior sweep and angulation to long axis of gluteus minimus tendon



Structures Identified:

- Anterior trochanteric facet

- Lateral trochanteric facet
- Gluteus minimus tendon
- Gluteus medius tendon
- Iliotibial band

Goals for Scan:

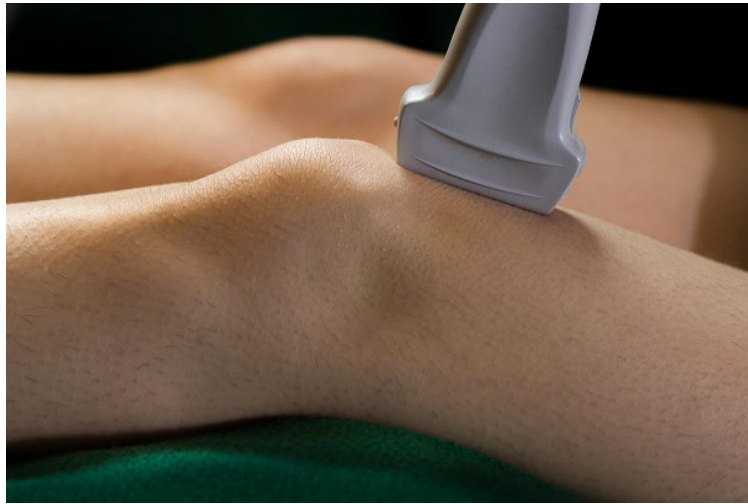- Greater trochanter has defined periosteal border
- Gluteus medius tendon is visualized

Knee

Anterior Suprapatellar Longitudinal

Position:

- Knee in slight flexion with transducer parallel to quadriceps tendon, sweeping from medial to lateral gutters



Structures Identified:

- Quadriceps tendon
- Femur
- Patella
- Suprapatellar joint recess

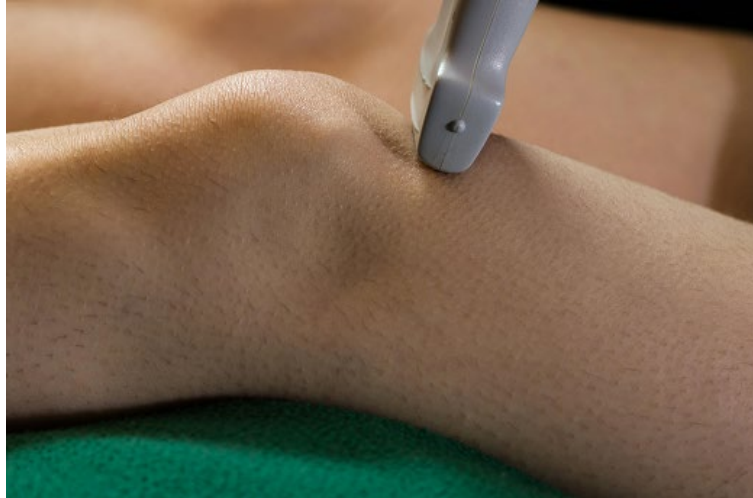Goals for Scan:

- Proximal patella and femur have defined periosteal border
- Quadriceps tendon continuously visible to distal insertion on patella /minimal anisotropy

Anterior Suprapatellar Transverse

Position:

- Knee in slight flexion with transducer transverse over quadriceps tendon, sweeping from medial to lateral gutters



Structures Identified:

- Quadriceps tendon
- Femur
- Suprapatellar joint recess

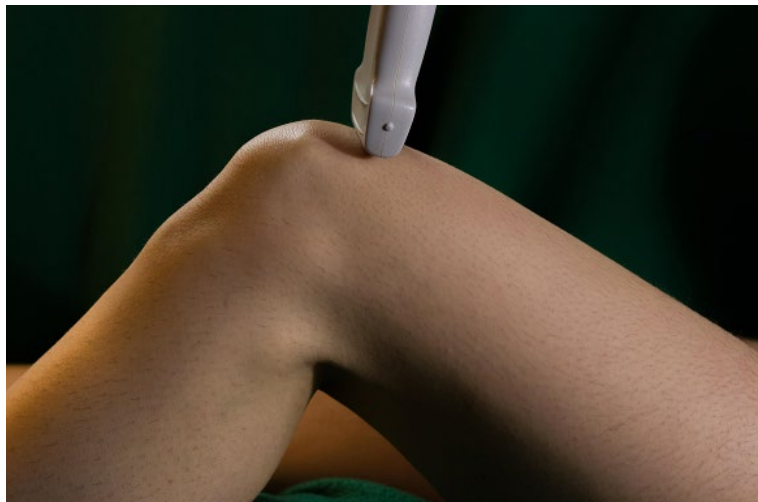
Goals for Scan:

- Femur has defined periosteal borders
- Quadriceps tendon visible

Anterior Suprapatellar Transverse in Maximum Flexion

Position:

- Knee in maximum flexion with transducer transverse to the distal femur



Structures Identified:

- Quadriceps tendon
- Femur
- Articular cartilage

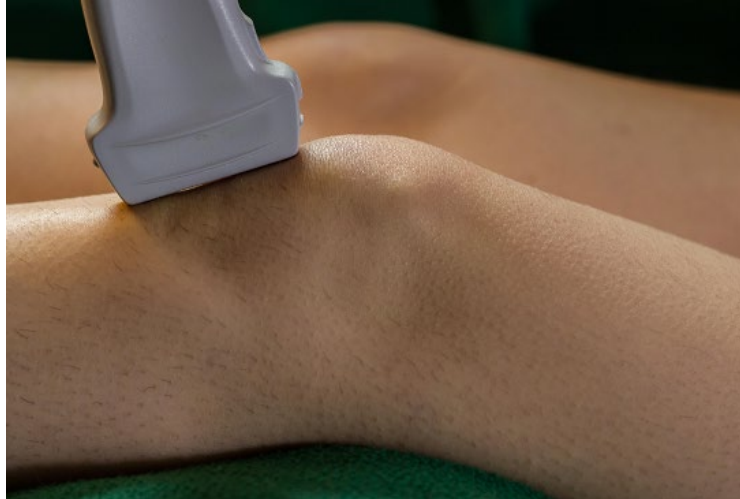Goals for Scan:

- Femur has defined bone borders
- Articular cartilage is visible as low signal structure superficial to femur

Anterior Infrapatellar Longitudinal

Position:

- Knee is in extension to slight flexion with transducer parallel to patellar tendon and scan from patella distal to tibial tuberosity



Structures Identified:

- Patellar ligament
- Patella
- Tibial tuberosity
- Enthesis
- Infrapatellar fat pad

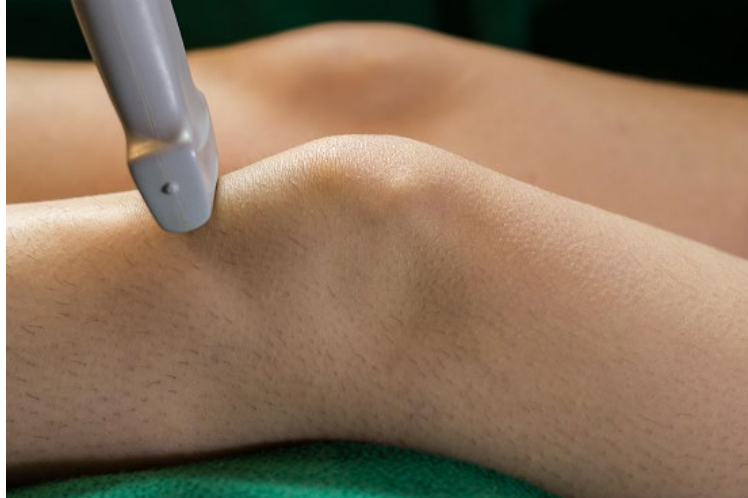Goals for Scan:

- Patella and tibia have defined borders
- Patellar ligament visible without anisotropy

Anterior Infrapatellar Transverse

Position:

- Knee is in 30° flexion with transducer transverse to patellar tendon and scan from patella distal to tibial tuberosity



Structures Identified:

- Patellar ligament
- Tibia
- Entesis
- Infrapatellar bursa

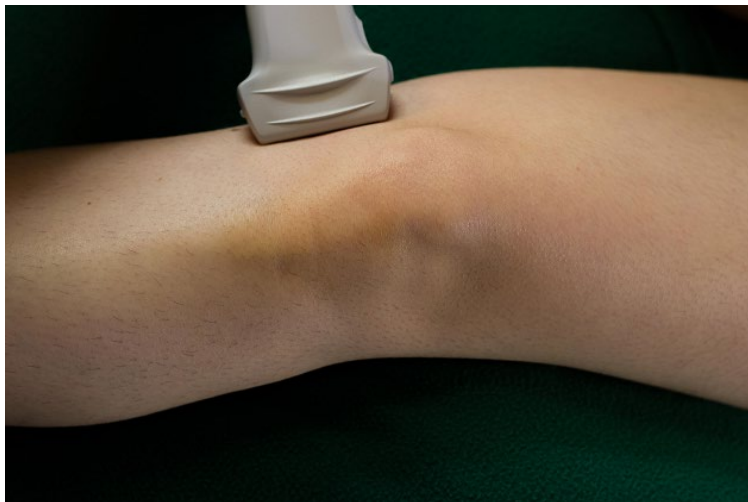Goals for Scan:

- Tibia has defined borders
- Patellar ligament visible without anisotropy

Medial longitudinal:

Position:

- Knee in extension to slight flexion with transducer longitudinal to the femur and centered over the medial knee joint



Structures Identified:

- Medial collateral ligament

- Medial meniscus
- Femur
- Tibia

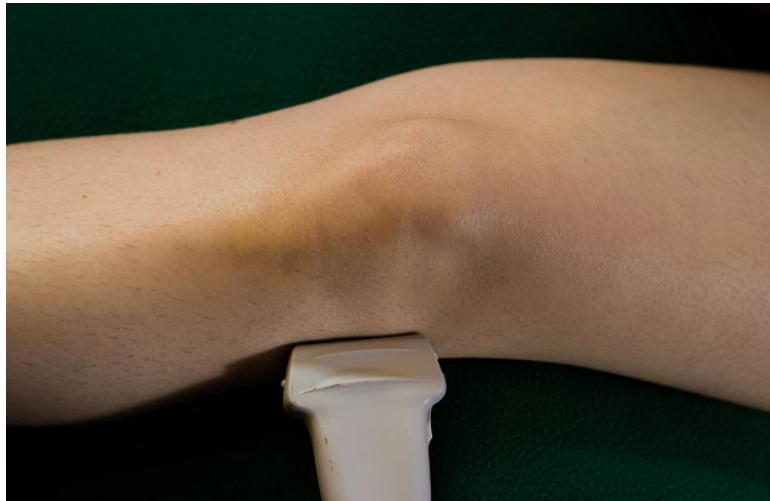Goals for Scan:

- Femur and tibia landmarks have defined periosteal borders
- Medial meniscus visible with minimal meniscus anisotropy
- Medial collateral ligament visible

Lateral Longitudinal

Position:

- Knee in extension to slight flexion with transducer longitudinal to the femur and centered over the lateral knee joint



Structures Identified:

- Lateral collateral ligament
- Lateral meniscus
- Femur
- Tibia
- Fibula
- Iliotibial band
- Gerdy's tubercle
- Popliteus tendon

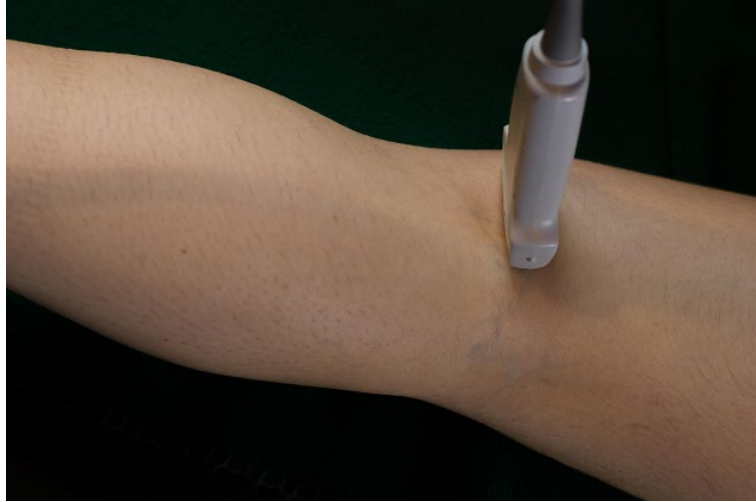Goals for Scan:

- Femur, tibia and fibula have defined periosteal borders
- Lateral meniscus visible with minimal meniscus anisotropy
- Lateral collateral ligament visible
- Iliotibial band visible

Posterior Transverse`

Position:

- Patient prone with knee extended and transducer is transverse to the femur



Structures Identified:

- Semimembranosus tendon
- Femur
- Medial head of gastrocnemius
- Articular cartilage

Goals for Scan:

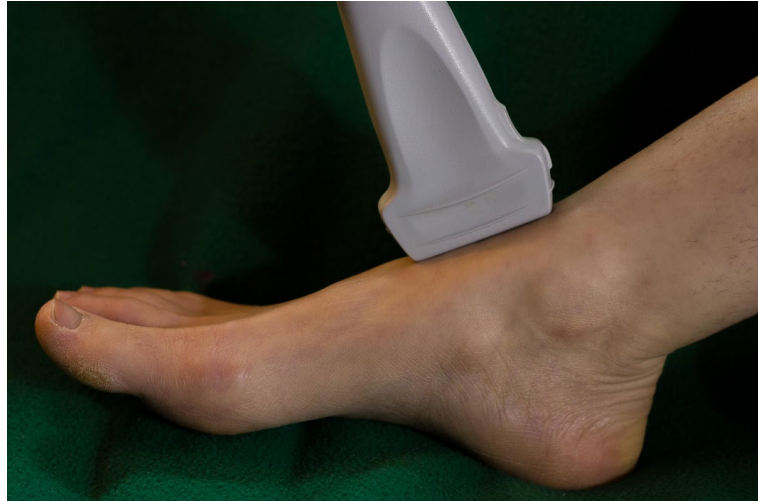- Proximal medial head of gastrocnemius is clearly visible
- Semimembranosus tendon visible with minimal anisotropy
- Medial femoral condyle has defined bone border

Ankle

Anterior Longitudinal

Position:

- Ankle in slight plantar extension with transducer parallel to the tibia crossing the tibial talar joint, sweeping from medial to lateral



Structures Identified:

- Tibia
- Talus
- Navicular
- Cuneiform
- Articular fat pad
- Articular cartilage

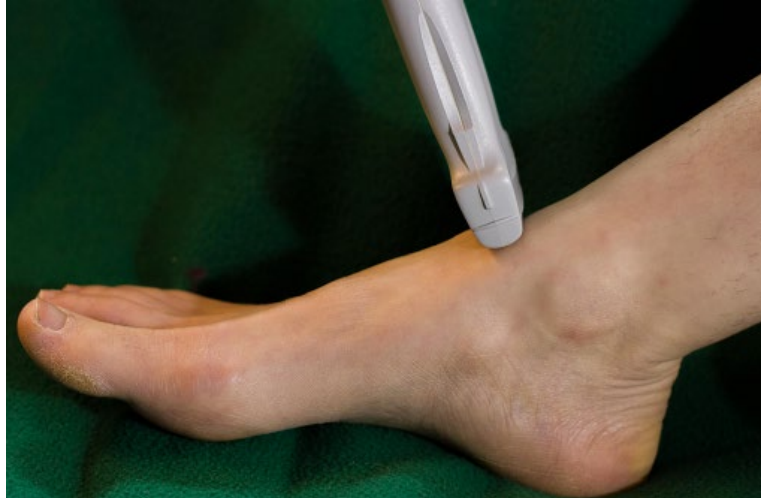Goals for Scan:

- Distal tibia, and talus have defined periosteal borders
- Articular cartilage of talus is anechoic and fat pad is well defined

Anterior Transverse

Position:

- Ankle in slight plantar extension with transducer transverse to the tibia crossing the tibial talar joint, sweeping from proximal to distal



Structures Identified:

- Talus
- Articular capsule
- Articular cartilage

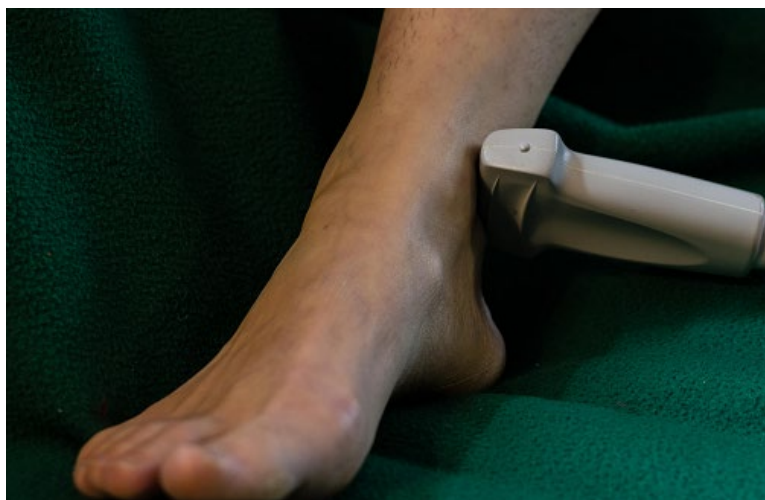Goals for Scan:

- Talar dome has defined periosteal borders and thin anechoic cartilage layer
- Extensor tendons visible with minimal anisotropy

Perimalleolar Medial Transverse

Position:

- Ankle in neutral position with the transducer transverse to the tibia with sweep from proximal to distal medial malleolus



Structures Identified:

- Tibia
- Talus

- Tibialis posterior tendon
- Flexor digitorum longus
- Posterior tibial artery
- Posterior tibial nerve
- Flexor hallucis longus tendon

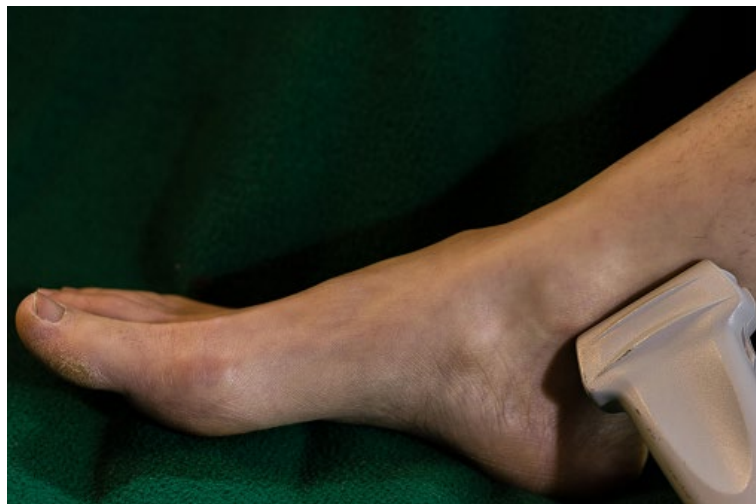Goals for Scan:

- Tibia and talus have defined periosteal borders
- Tibialis posterior tendon, and flexor digitorum longus tendon are visible without anisotropy
- Posterior tibial neurovascular bundle is seen without obliteration of veins by transducer pressure

Perimalleolar Medial Longitudinal

Position:

- Ankle in neutral position with transducer parallel to tibia, sweeping from proximal to distal medial malleolus



Structures Identified:

- Tibia
- Tibialis posterior tendon

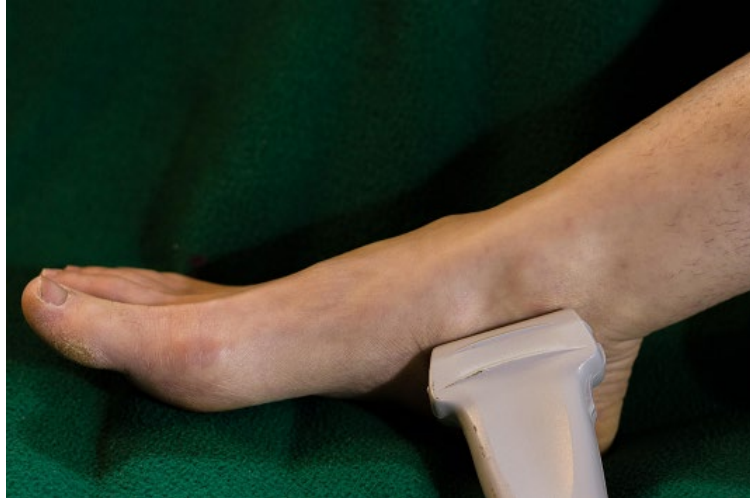Goals for Scan:

- Tibia with a well-defined periosteal border
- Tibialis posterior tendon and/or flexor digitorum longus tendon is visualized over at least 70% of the image

Inframalleolar Medial Longitudinal

Position:

- Ankle in neutral position with transducer parallel to tibia, sweeping from distal medial malleolus to the posterior tibial tendon insertion on the navicular bone



Structures Identified:

- Tibialis posterior tendon
- Navicular
- Plantar calcaneo-navicular ligament

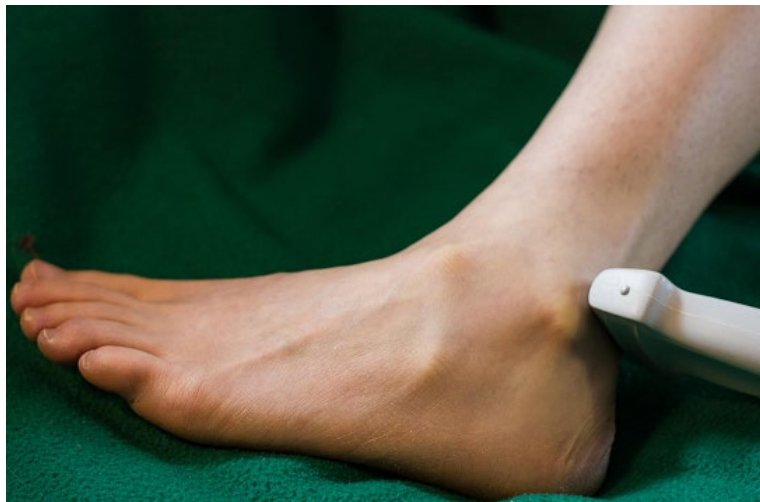Goals for Scan:

- Navicular has a defined periosteal border
- Tibialis posterior tendon is continuously visible from left side of screen to insertion on Navicular with minimal anisotropy

Perimalleolar Lateral Transverse

Position:

- Ankle in neutral position with transducer transverse to fibula, sweeping from proximal to distal lateral malleolus



Structures Identified:

- Fibula
- Tibia

- Peroneus brevis tendon
- Peroneus longus tendon

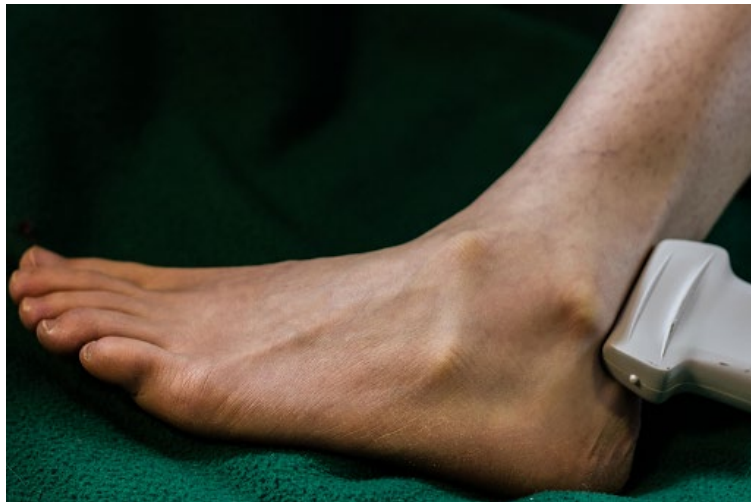Goals for Scan:

- Fibula with defined periosteal borders
- Peroneus longus and brevis tendons are visible without anisotropy

Perimalleolar Lateral Longitudinal

Position:

- Ankle in neutral position with transducer longitudinal to the fibula, sweeping from proximal to distal lateral malleolus



Structures Identified:

- Fibula
- Peroneus brevis tendon
- Peroneus longus tendon

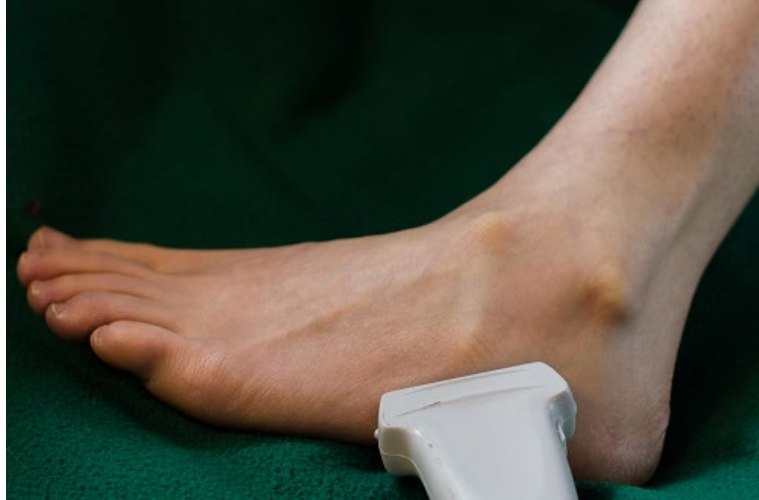Goals for Scan

- Fibula with a well-defined periosteal border
- Peroneal longus and brevis tendons are visualized over at least 70% of the image

Inframalleolar Lateral Longitudinal

Position:

- Ankle in neutral position with transducer longitudinal to the fibula, sweeping from distal lateral malleolus to peroneus brevis tendon insertion onto 5th metatarsal



Structures Identified:

- Calcaneus
- Tuberosity 5th metatarsal
- Peroneus brevis tendon
- Lateral subtalar joint

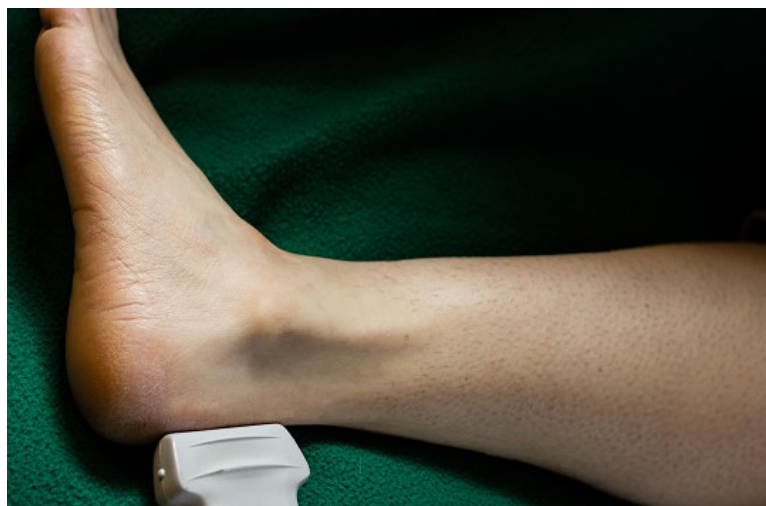Goals for Scan:

- 5th metatarsal base has a defined periosteal border
- Peroneus brevis tendon is continuously visible from left side of screen to insertion on 5th metatarsal with minimal anisotropy

Posterior Longitudinal:

Position:

- Ankle in neutral position with transducer longitudinal to the Achilles tendon



Structures Identified:

- Calcaneus

- Achilles tendon
- Retrocalcaneal fat pad
- Retrocalcaneal bursa
- Entesis

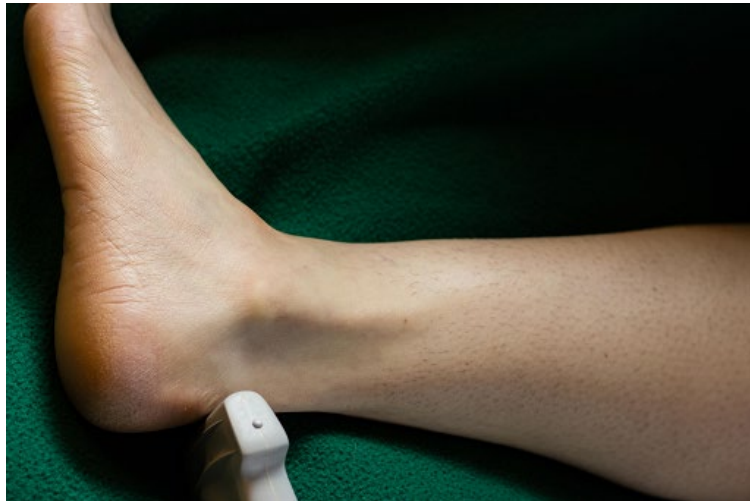Goals for Scan:

- Calcaneus has a defined periosteal border
- The Achilles tendon is visible from left side of screen to insertion on calcaneus with minimal anisotropy
- The retrocalcaneal bursa and fat pad are well defined

Posterior Transverse

Position:

- Ankle in neutral position with transducer transverse to the Achilles tendon



Structures Identified:

- Calcaneus
- Achilles tendon
- Retrocalcaneal bursa

Goals for Scan:

- Calcaneus has defined periosteal border
- Retrocalcaneal bursa is visible and not compressed
- Achilles is visible without anisotropy

Plantar Longitudinal

Position:

- Ankle in neutral position with transducer longitudinal to the metatarsals



Structures Identified:

- Calcaneus
- Plantar aponeurosis

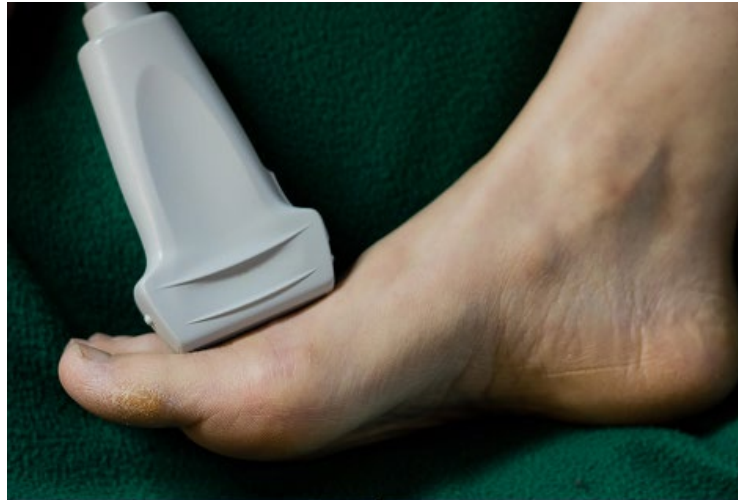Goals for Scan:

- Calcaneus has defined periosteal border
- Plantar fascia is visible without anisotropy from the origin on the calcaneus to a point at least 2cm distal to the origin.

Dorsal Longitudinal MTP Joint

Position:

- MTP in neutral position with transducer longitudinal to metatarsal



Structures Identified:

- Metatarsal
- Phalanx
- Extensor tendon
- Synovial reflection
- Joint cleft with fat

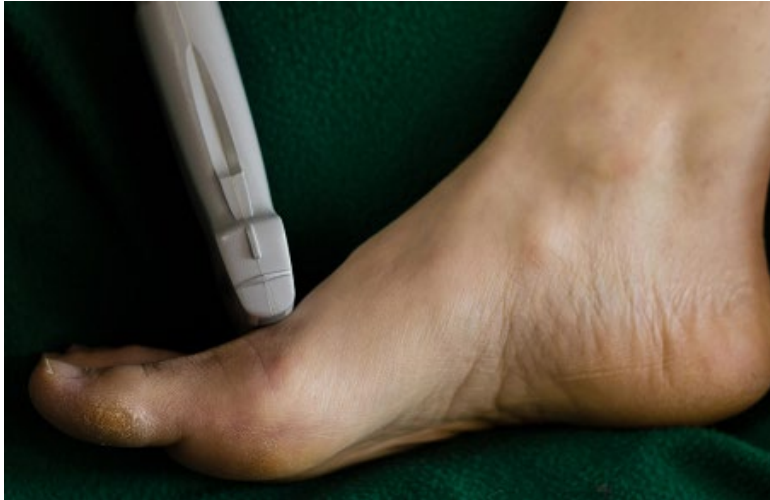Goals for Scan:

- Metatarsal head and proximal portion of proximal phalanx have definable periosteal border
- Soft tissue structures dorsal to bone contour can be distinguished (Capsular structures or extensor tendon)

Dorsal Transverse 1st MTP Joint

Position:

- MTP in neutral position with transducer transverse to metatarsal



Structures Identified:

- Phalanx
- Extensor digitorum tendon
- Synovial reflection

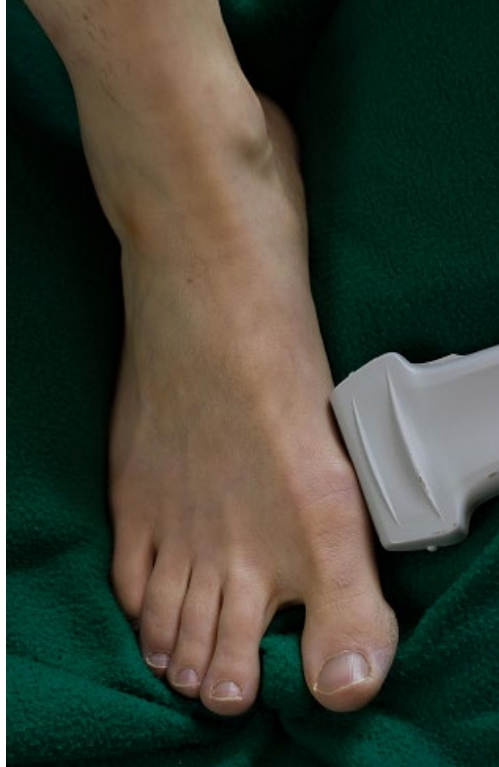Goals for Scan:

- Metatarsal head and proximal phalanx have definable periosteal borders
- Extensor tendons visible with minimal anisotropy

Medial and Lateral longitudinal MTP Joint

Position:

- MTP in neutral position with transducer longitudinal to metatarsal in medial joint line (1st) and lateral joint line (5th)



Structures Identified:

- Metatarsal
- Phalanx
- Joint capsule

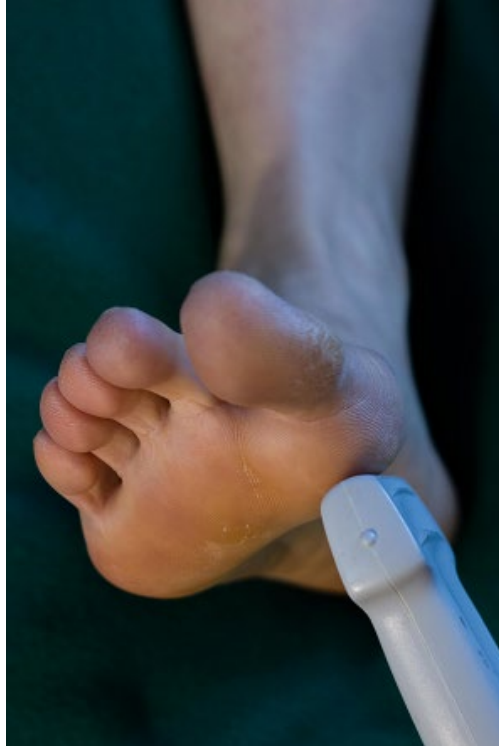Goals for Scan:

- Metatarsal head and proximal phalanx have definable periosteal borders
- Capsular structures or ligament are visible

Plantar Longitudinal 1st MTP Joint

Position:

- MTP in neutral position with transducer longitudinal to metatarsal



Structures Identified:

- Metatarsal
- Phalanx
- Articular cartilage
- Flexor hallucis tendon

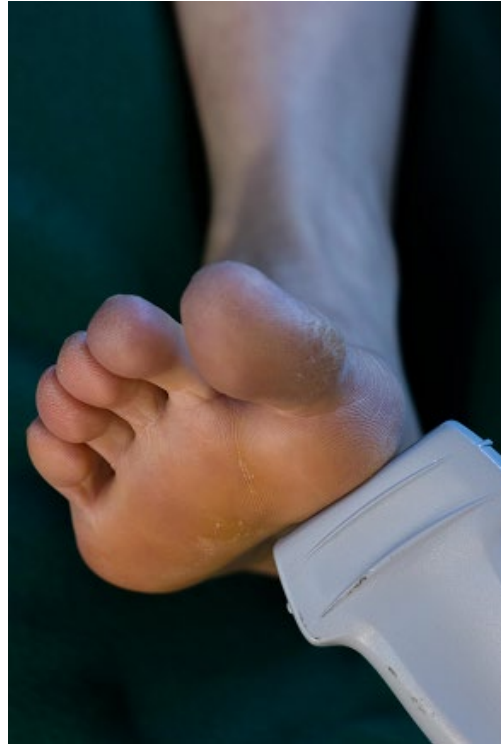Goals for Scan:

- Metatarsal head and proximal phalanx are visible
- Flexor tendon visible as landmark

Plantar Transverse 1st MTP Joint

Position:

- MTP in neutral position with transducer transverse to metatarsal



Structures Identified:

- Metatarsal
- Sesamoid
- Flexor hallucis longus

Goals for Scan:

- Sesamoid bones have definable periosteal borders
- Flexor tendon is defined

Pediatric Specific Views

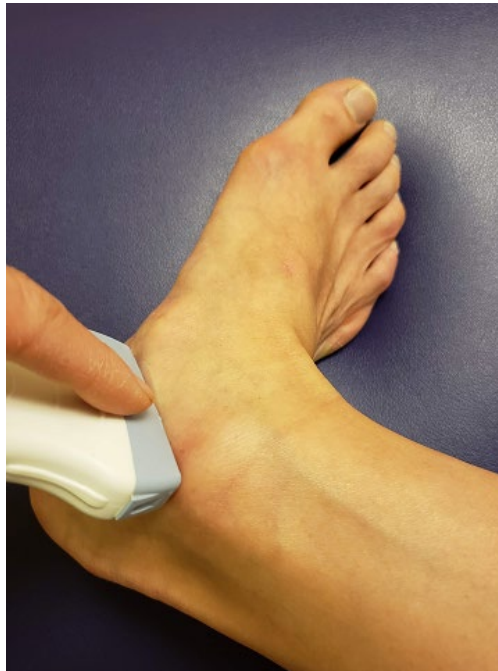These images were taken with an adult subject for better visualization of bony landmarks.

Ankle

Medial Subtalar

Position:

- Ankle in eversion with proximal tip of the transducer on the distal tip of the medial malleolus and angled approximately 45 degrees anteriorly to cross the subtalar joint space with dynamic movement of the calcaneus (inversion/eversion) to demonstrate the subtalar joint space, then sweep posteriorly and anteriorly



Structures identified:

- Tibia
- Talus
- Calcaneus
- Sustentaculum tali

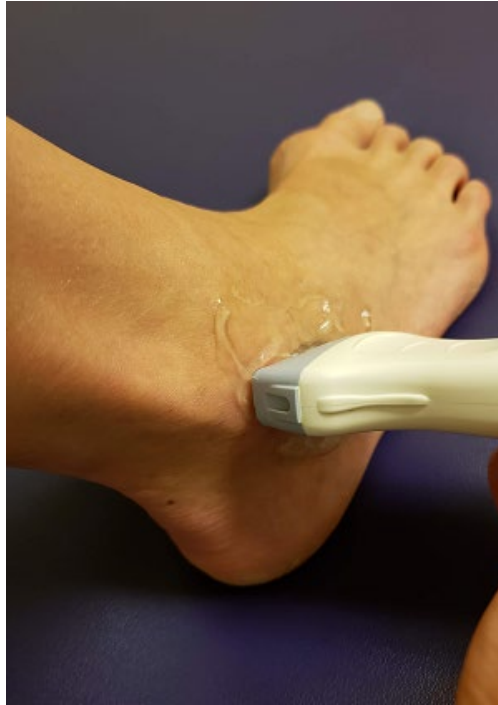Goals for Scan:

- Talus and calcaneus have defined periosteal borders
- Dynamic scanning

Anterior Subtalar

Position:

- Ankle in inversion with proximal tip of the transducer on the distal tip of the lateral malleolus and angled approximately 45 degrees anteriorly to cross the sinus tarsi with dynamic movement of the calcaneus (inversion/ eversion) to demonstrate the subtalar joint space, then sweep posteriorly and anteriorly



Structures identified:

- Tibia
- Talus
- Calcaneus
- Sinus tarsi

Goals for Scan:

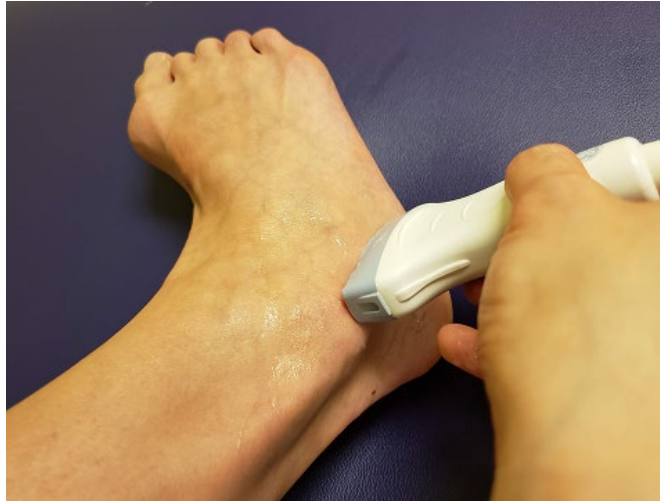- Talus and calcaneus have defined periosteal borders
- Dynamic scanning

Lateral Subtalar

Position:

- Ankle in inversion with proximal tip of the transducer on the distal tip of the lateral malleolus and pointed caudally to cross the subtalar joint space with

dynamic movement of the calcaneus (inversion/eversion) to demonstrate the subtalar joint space, then sweep posteriorly and anteriorly



Structures identified:

- Tibia
- Talus
- Calcaneus

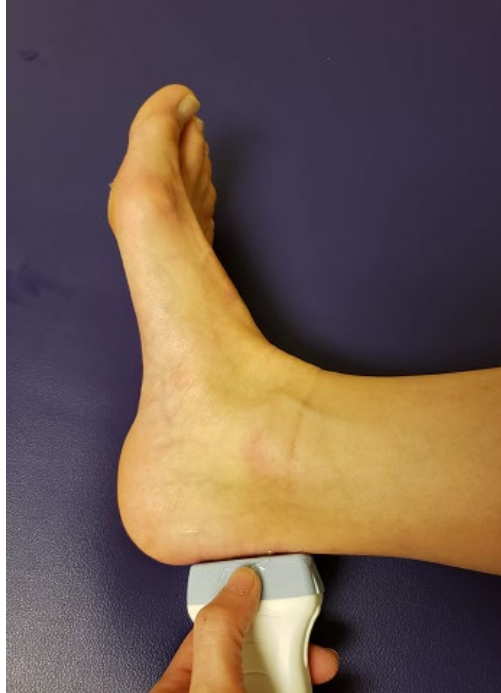Goals for Scan:

- Talus and calcaneus have defined periosteal borders
- Dynamic scanning

Posterior Subtalar

Position:

- Ankle in neutral position with transducer placed longitudinal to Achilles tendon, crossing over the posterior recess of the subtalar joint with dynamic movement of the calcaneus to demonstrate the subtalar joint, sweep laterally and medially



Structures identified:

- Tibia
- Talus
- Calcaneus

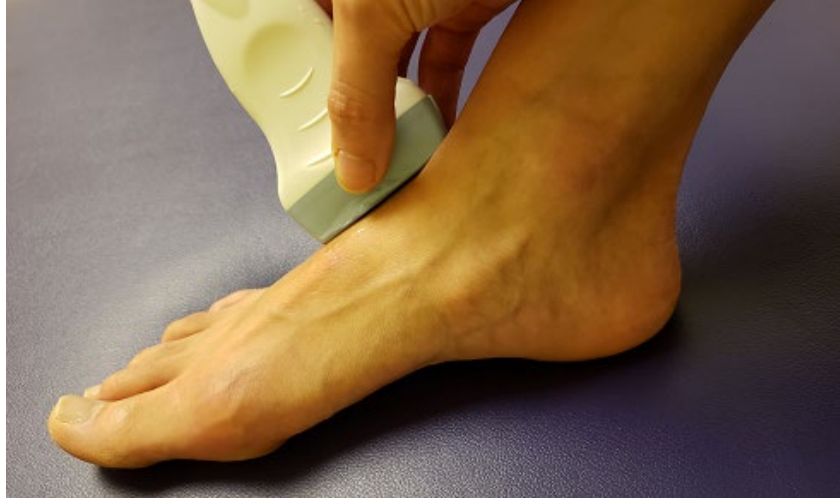Goals for Scan:

- Tibia, Talus and calcaneus have defined periosteal borders
- Minimal anisotropy of Kager's fat pad

Talonavicular

Position:

- Ankle in slight plantar flexion with transducer placed parallel to tibia, crossing over the talonavicular joint, then sweep laterally and medially



Structures identified:

- Talus
- Navicular

Goals for Scan:

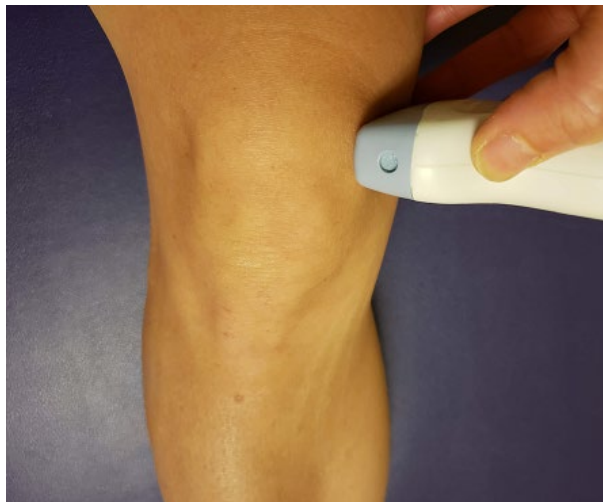- Talus and navicular bones have defined periosteal borders

Knee

Medial parapatellar

Position:

- Knee in slight flexion with transducer transverse to the femur and on the medial edge of the patella and medial aspect of the femur, then sweep distally and proximally along the parapatellar recess



Structures identified:

- Femur
- Patella
- Medial parapatellar recess
- Medial patellar retinaculum

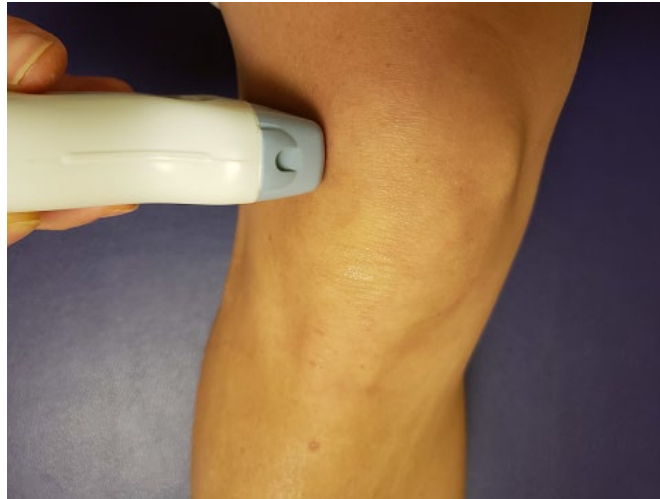Goals for Scan:

- Femur and patella have defined periosteal borders
- Retinaculum visible

Lateral parapatellar

Position:

- Knee in slight flexion with transducer transverse to femur and on the lateral edge of the patella and lateral aspect of the femur, then sweep distally and proximally along the parapatellar recess



Structures identified:

- Femur
- Patella
- Lateral parapatellar recess
- Lateral patellar retinaculum

Goals for Scan:

- Femur and patella have defined periosteal borders
- Retinaculum visible

APPENDIX F: DOCUMENTATION TEMPLATE

RhUS documentation serves as an accurate recording of findings for the medical record and for communication of findings to referring providers. The length and style of RhUS documentation varies among providers, regions and health care systems. While many experienced sonographers may utilize a streamlined template approach, for the trainee learning RhUS, educators may prefer the use of a more comprehensive document to assure all target areas have been scanned and appropriate pathologic findings confirmed when present. Therefore, documentation should be customized to specific programmatic needs

The following are examples of a normal knee scan with both a streamlined and a comprehensive template, as well as suggested interventional language, where appropriate. Areas in bold should be tailored to individual patient scans.

Documentation components for a complete versus a limited examination will vary among providers and local regulatory requirements.

General recommendations for RhUS Documentation (diagnostic and interventional reports):

Study Type:

Date:

Study Indication:

Site:

Equipment: machine and transducer (type and frequency) utilized

Views performed:

Findings:

Impression:

Image Location: (if stored separately from the report)

Example Option 1: Streamlined Knee Template

Rheumatologic Ultrasound (RhUS)

Date:

Study Indication:

Site: Knee

Equipment: **XXX (ultrasound machine)** with **XXX MHz (Linear/Curvilinear)**

Transducer

Views performed: Suprapatellar longitudinal, Suprapatellar transverse, Suprapatellar in maximum flexion transverse, Infrapatellar longitudinal,

Infrapatellar transverse, Medial longitudinal, Lateral longitudinal, Posterior transverse

Orientation: Unless noted, the right screen is distal, radial, fibular, or anatomic lateral

Findings:

The suprapatellar recess revealed a normal amount of fluid (4mm or less). The visualized femoral cartilage surfaces were intact without double contour sign or intrasubstance hyperechoic signal. The infrapatellar tendon is intact. There is no superficial or deep infrapatellar bursal hypertrophy. The lateral and medial menisci were visualized without perimeniscal cyst or evidence of displaced cartilage fragments. No Baker cyst was noted on the posterior view. The visualized muscle tissue had normal echotexture.

Impression: Normal knee ultrasound

Image Location: (if stored separately from the report)

Example Option 2: Comprehensive Knee Template

Rheumatologic Ultrasound (RhUS)

Date:

Study Indication:

Site: Knee

Equipment: **XXX (*ultrasound machine*)** with **XXX MHz (*Linear/Curvilinear*)**

Transducer

Orientation: Unless noted, the right screen is distal, radial, fibular, or anatomic lateral

Findings:

Suprapatellar Longitudinal View: The femur and proximal patella were visualized and normal with no erosions. The quadriceps tendon was visualized to its insertion on the proximal patella and was normal. The synovial folds were seen and normal, with no joint effusion.

Suprapatellar Transverse View: The quadriceps tendon was normal. No joint effusion was noted.

Suprapatellar Maximum Flexion Transverse View: The quadriceps tendon was normal. The femur had a normal bony contour with no osteophytes. The articular cartilage had a normal thickness, and no crystalline deposition.

Infrapatellar Longitudinal View (Proximal): The patellar ligament was seen at its origin on the distal patella and is normal. The infrapatellar fat pad is normal.

Infrapatellar Longitudinal View (Distal): The patellar ligament was seen at its insertion onto the tibial tuberosity and was normal. The infrapatellar fat pad was normal.

Infrapatellar Transverse View: The patellar ligament was seen and normal. The tibia was normal. There is no bursal hypertrophy.

Medial Longitudinal View: The femur and tibia are visualized and were normal with no erosions or osteophytes. No joint effusion was seen. The medial meniscus was visualized without any cystic changes. The medial collateral ligament was visualized and normal.

Lateral Longitudinal View: The femur and tibia are visualized and are normal with no erosions or osteophytes. No joint effusion is seen. The lateral meniscus is visualized without any cystic lesions. The medial collateral ligament, iliotibial band and popliteus tendon were visualized and normal.

Posterior Transverse View: The femur and articular cartilage were seen and normal. The semimembranosus tendon and medial head of the gastrocnemius were seen and no popliteal cyst was present.

Impression: Normal knee ultrasound

Image Location: (if stored separately from the report)

RhUS Guided Interventional Procedure Documentation:

Interventional procedure documentation may be combined with the diagnostic reports above, when appropriate, or the RhUS portion may be documented separately from the procedure. Recommended template features are as follows.

Rheumatologic Ultrasound (RhUS)

Procedure Type:

Date:

Study Indication:

Site:

Equipment: **XXX (ultrasound machine)** with **XXX MHz (Linear/Curvilinear)**
Transducer

Procedure: **document procedure performed plus ultrasound visualization (below)**

Direct ultrasound visualization:

Real time (in-plane/out-of-plane) ultrasound visualization was used to guide needle placement.

Indirect ultrasound visualization:

Ultrasound guidance was used to mark the area for needle placement via the paperclip (or other) technique.

Impression:

Image Location: (if stored separately from the report)

APPENDIX G: SOURCE DOCUMENTS

American College of Rheumatology (ACR) RhMSUS Candidate Handbook 2017

AIUM Practice Parameter for the Performance of a Musculoskeletal Ultrasound Examination 2012.

American College of Rheumatology Core Curriculum Outline for Rheumatology Fellowship Programs, Updated June 2015. Co-Chairs: Marcy B. Bolster, MD and Calvin R. Brown, Jr. MD. For the NAS Working Group of the ACR Committee on Training and Workforce.

American College of Rheumatology Musculoskeletal Ultrasound Taskforce: Ultrasound in American rheumatology practice: Report of the American College of Rheumatology Musculoskeletal Task Force. *Arthritis Care Res* 2010;62(9):1206-1219.

Brown AK, O'Connor PJ, Roberts TE, et al. Recommendations for musculoskeletal ultrasonography by rheumatologists: Setting global standards for best practice by expert consensus. *Arthritis Care Res* 2005; 53(1): 83-92.

Brown AK, O'Connor PJ, Roberts, TE, et al. Ultrasonography for rheumatologists: The development of specific competency based educational outcomes. *Ann Rheum Dis* 2006; 65:629-636.

Brown AK, Roberts TE, O'Connor PJ, et al. The development of an evidence-based educational framework to facilitate the training of competent rheumatologist ultrasonographers. *Rheumatology* 2007; 46:391-397.

Cannella AC, Kissin EY, Torralba KT, et al. Evolution of musculoskeletal ultrasound in the United States: Implementation and practice. *Arthritis Care Res* 2014; 66(1):7-13.

Collado P, Vojinovic J, Nieto JC, et al. Toward standardized musculoskeletal ultrasound in pediatric rheumatology: normal age-related ultrasound findings. *Arthritis Care Res* 2016;68:348-56.

Iagnocco A, Naredo E, Bijlsma JWJ. Becoming a musculoskeletal ultrasonographer. *Best Prac Res Clin Rheum* 2013; 27: 271-281.

Kissin EY, Niu J, Balint P, et al. Musculoskeletal ultrasound training and competency assessment program for rheumatology fellows. *J Ultrasound Med* 2013; 32:1735-1743.

Roth J, Ravagnani V, Backhaus M, Balint P, et al. Preliminary definitions for the sonographic features of synovitis in children. *Arthritis Care Res* 2017; 69:1217-23.

Smith J, Finoff JT Diagnostic and interventional musculoskeletal ultrasound: Part 1. Fundamentals. *PM&R* 2009;1:64-75.

Smith J, Finoff JT Diagnostic and interventional musculoskeletal ultrasound: Part 2. Clinical applications. *PM&R* 2009;1:162-177.

USSONAR Guides

Torralba K, Nishio MJ, Thiele R, Fairchild R, Choi K, Salto L, Cannella A, Kissin E.. Consensus Statements on Scanning Conventions and Documentation in Musculoskeletal Ultrasound. Abstract 72516. 2018 ACR/ARHP American College of Rheumatology Annual Meeting, Chicago IL, October 22, 2018

Torralba K, Nishio MJ, Thiele R, Fairchild R, Choi K, Salto L, Cannella A, Kissin E. Abstract Number 110 • Consensus-Building on a Rheumatology Musculoskeletal Ultrasound Scanning Protocol for Rheumatology Fellowship Programs. 2017 ACR/ARHP Annual Meeting. American College of Rheumatology Annual Meeting, San Diego CA, November 2017

2018 RhUS Mini-Curriculum Working Group

Primary Authors:

Amy C. Cannella, MD, MS, RhMSUS
Division of Rheumatology
University of Nebraska Medical Center
986270 Nebraska Medical Center
Omaha, NE 68198-6270
Phone: 402-559-8168
Fax: 402-559-6788
Email: acannella@unmc.edu

Eugene Y. Kissin, MD, RhMSUS
Division of Rheumatology
Boston University
72 East Concord Street, Evans 504
Boston, MA 02118
Phone:
Fax:
Email: eukissin@bu.edu

Karina D. Torralba, MD, MACM,
RhMSUS
Division of Rheumatology
Loma Linda University
11234 Anderson Street, MC 1521
Loma Linda, CA 92354

Phone: 909-558-4909
Fax: 909-558-0396
Email: KTorralba@llu.edu

Clara Lin, MD, RhMSUS
University of Colorado
13123 East 16th Avenue
Aurora, CO 80016
Phone 720-777-6132
Fax: 720-777-7341
Email:
clara.lin@childrenscolorado.org

Jay B. Higgs, MD, RhMSUS
Uniformed Services University of the
Health Sciences
MCHE-ZDM-R
Brooke Army Medical Center
3551 Roger Brooke Drive
JBSA Ft Sam Houston TX 78234-4504
Phone: 210-916-0797
Fax: 210-916-5222
Email: jayluthier1@gmail.com/210-508-8649

Co-Authors:

Marcy Bolster, MD
Massachusetts General Hospital
55 Fruit St
Boston, MA 02114
Phone: 617-726-2000
Fax: 617-726-2870
Email: mbolster@partners.org

Paul J. DeMarco, MD, RhMSUS
Arthritis & Rheumatism Associates, PC
2730 University Blvd W Ste 310
Wheaton, MD 20902
Phone: 301-942-7600
Fax: 301-942-3132
Email: Pauljdemarco2@icloud.com

M. Jane Nishio, MD, RhMSUS
Stanford University Medical School
1840 San Miguel Drive, Suite 203
Walnut Creek, CA 94598
Phone: 925-280-9400
Fax: 925-256-0448
Email: nishiom@sbcglobal.net

Ed Oberle, MD, RhMSUS
Nationwide Children's Hospital
700 Childrens Drive
Columbus, OH 43205
Phone: 614-722-5525
Fax: 614-722-3194

Chaim Putterman, MD
Albert Einstein College of Medicine
Jack and Pearl Resnick Campus
1300 Forchheimer Building, Room
701N
Bronx, NY 10461
Phone: 718-430-4266
Fax: 718-430-4268

Johannes Roth, MD, RhMSUS
CHEO Research Institute
401 Smyth Road
Ottawa, Ontario Canada
K1H 8L1
jroth@cheo.on.ca
Phone: 613-7377600 ext 1015
Fax: 613-7384297

Tracy Ting, MD, RhMSUS
Cincinnati Children's Hospital Medical
Center
7777 Yankee Rd
Liberty Township, OH 45044
Phone: 513-636-4676
Fax: 513-636-5568

Patricia Vega-Fernandez, MD, RhMSUS
Children's Physician Group
Rheumatologists
2015 Upper Gate Dr.
Atlanta, GA 30322
Email: pvegafe@emory.edu
Phone: 404-785-2000

Contributors:

Catherine Bakewell, MD, RhMSUS
Rheumatology Intermountain Medical
Group
389 S. 900 East
Salt Lake City, UT 84102
Phone: 385-282-2750
Fax 385-282-2751

Narandra Bethina, MD, RhMSUS
The University of Vermont Medical
Center
111 Colchester Ave
Main Campus, East Pavilion, Level 5
Burling, Vermont 05401
Phone: 802-847-4574
Fax: 802-847-9695

Amy Evangelisto, MD, RhMSUS
Arthritis, Rheumatic & Back Disease
Associates
2301 E Evesham Rd Bldg 800, Suite
115
Voorhees, NJ 08043-1559
Phone: 856-424-5005
Fax: 856-424-4716

Gurjit S. Kaeley, MD, RhMSUS
UF Health Jacksonville
655 W 8th St Floor 1
Jacksonville, FL 32209
Phone: 904-383-1005
Fax: 904-633-0033

Minna J. Kohler, MD, RhMSUS
Massachusetts General Hospital
55 Fruit St
Boston, MA 02114
Phone: 617-726-2000
Fax: 617-643-1274

Gary Kunkel, MD, RhMSUS
University of Utah Medical Group
50 N Medical Dr Clinic 2
Salt Lake City, UT 84132
Phone: 801-581-7724

Bethany Marston, MD
University- Rochester
601 Elmwood Ave #777
Rochester, NY 14642
Phone: 585-275-4733

Daniel G. Malone, MD
3437 Edgehill Pkwy
Madison, WI 53705-1450
Phone: 608-655-8181
Fax: 608-655-8224

Anthony Reginato, MD
375 Wampanoag Trl
Suite 302C
Riverside, RI 02915
Phone: 401-649-4040

Jonathan Samuels, MD, RhMSUS
Rheumatology NYU Langone Health
333 E 38th St
Floor 4
New York, NY 10016
Phone: 646-501-7400

Ralf Thiele, MD, RhMSUS
University of Rochester Medical
Center
400 Reed Creek Dr.
Suite 240
Rochester, NY 14623
Phone: 585-276-300

Acknowledgements

We would like to thank Marcy Bolster, MD and Chaim Putterman, MD for their assistance from the ACR.

We would like to thank the following individuals for their collaboration in the development of the RhUS curriculum, including discussion and review:

Myma Aldayda, MD; Rany Al Haj, MD; Jon A Arnason, MD; Fawad Aslam, MD; Robert Fairchild, MD; Michelene Hearth-Holmes, MD, MEd; Lily Kao, MD; Prashant Kaushik, MD; Karim R. Masri, MD; Deborah Parks, MD; Elizabeth Russell, MD; Victor Rao, MD; Shruti Sanghvi, MD; Veronika Sharp, MD; Wilmer Sibbitt, MD; Darren Tabechian, MD; Akaluck Thatayatikom, MD; Ian Ward, MD.