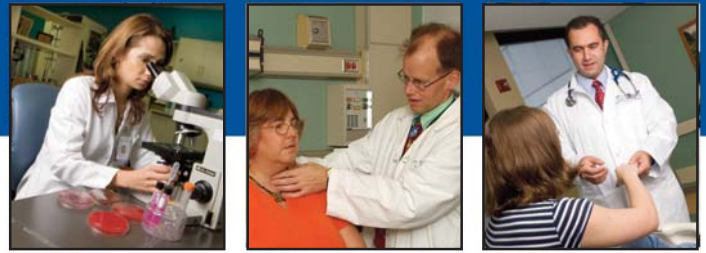


# Academic Physician *Quarterly*

A DEPARTMENT OF MEDICINE BULLETIN



**UF** UNIVERSITY of  
**FLORIDA**  
College of Medicine  
Jacksonville

## FOCUS

Page 2

## GME CORNER

Page 4

## CLINICAL CASE

Page 4

## RX UPDATES

Page 7

## NEWS AND NOTES

Page 7

## SHANDS BRAND

Page 8

## CHAIRMAN'S MESSAGE

Dear colleagues:

On behalf of the Department of Medicine at the University of Florida College of Medicine-Jacksonville I would like to wish you a happy new year. I hope you all had a wonderful holiday season with family and friends.

With the inauguration of the 2010 we will be in our fourth year of launching the Academic Physician Quarterly (APC) newsletter. The previously published issues of the APC are on our website at <http://hscj.ufl.edu/im/archives.asp>.



I am proud to assure you that the state of the Department is strong. We have maintained a strong core residency program and we have now completed the development of all subspecialties and have established training programs in each one. The last subspecialty training program to be added in July 1st, 2010 will be in Rheumatology and Immunology. If all goes as planned, this training program will be launched as a joint effort with the Mayo Clinics in Jacksonville. This collaborative accomplishment is an extension of our efforts to reach out to all the teaching and patient care institutions in our community.

I hope you enjoy reading through the pages of this issue. As always if you have any suggestions on how to improve our services please feel free to contact me personally.

Arshag D. Mooradian, M.D.  
Professor of Medicine  
Chairman, Department of Medicine

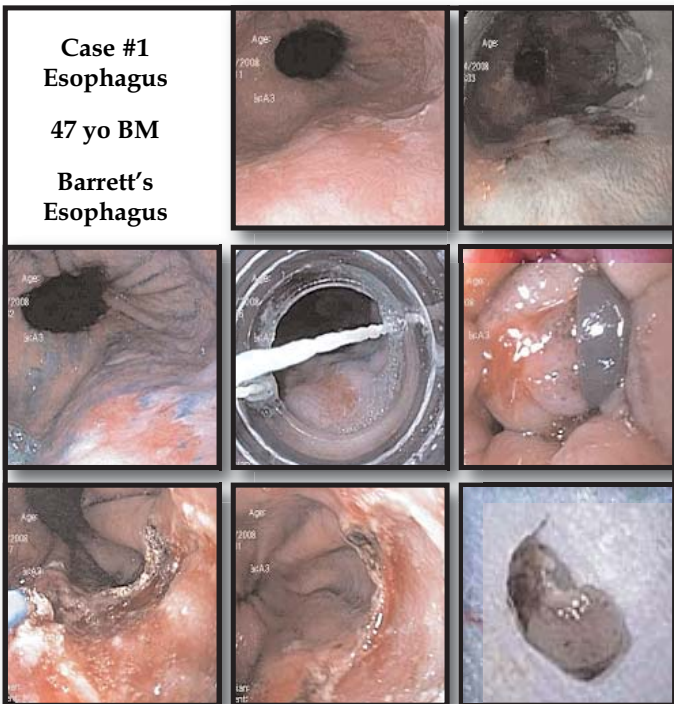

**Juan C. Munoz, M.D.**  
**Assistant Professor of Medicine**  
**Division of Gastroenterology**

**Endoscopic Mucosal Resection (EMR)**

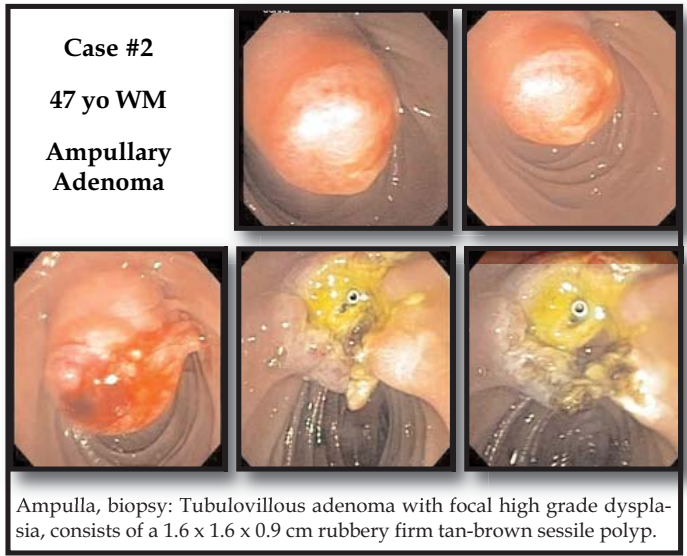
Endoscopic Mucosal Resection (EMR) is a new minimally invasive endoscopic technique used to locally excise lesions confined to the superficial mucosa avoiding the need for open surgery. Its main role is in the treatment of advanced dysplasia and early gastrointestinal cancers. The EMR was originally described as a therapy for early gastric cancer. Japanese physicians have used EMR for almost two decades.

In the Western world, the predominant indication for EMR in the upper gastrointestinal tract is the staging and treatment of advanced dysplasia and early neoplasia in Barrett's esophagus (Case #1).



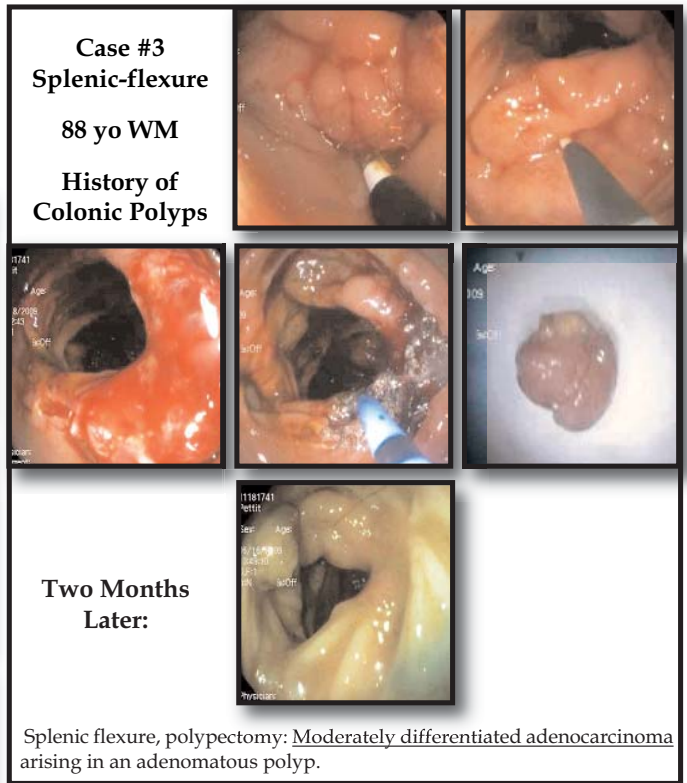
Squamocolumnar with intestinal (goblet cell) metaplasia consistent with Barrett's esophagus and fibrinopurulent inflammatory exudate. No dysplasia seen.

Recently its use has expanded as a therapeutic option for ampullary adenomas (Case #2), small/localized colorectal cancer (Case #3-4), and large colorectal polyps (Case #5-6).



**Case #2**  
**47 yo WM**  
**Ampullary Adenoma**

Ampulla, biopsy: Tubulovillous adenoma with focal high grade dysplasia, consists of a 1.6 x 1.6 x 0.9 cm rubbery firm tan-brown sessile polyp.




**Case #3**  
**Splenic-flexure**  
**88 yo WM**  
**History of Colonic Polyps**

**Two Months Later:**

Splenic flexure, polypectomy: Moderately differentiated adenocarcinoma arising in an adenomatous polyp.

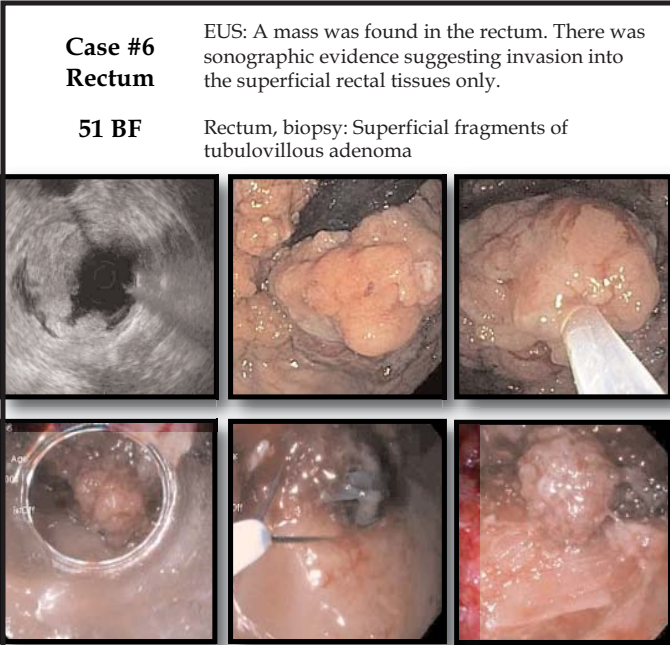
**Case #4**  
**Hepatic Flexure**  
 75 yo WM  
 Personal Hx of Colonic Polyps



**One Year Later:**

20 mm sessile polyp with focal high grade dysplasia at the hepatic flexure

**Case #6**  
**Rectum**  
 51 BF  
 Rectum, biopsy: Superficial fragments of tubulovillous adenoma



**FINAL DIAGNOSIS** rectum, biopsies: Multifocal intramucosal adenocarcinoma with focal invasion of the muscularis mucosa and superficial portion of submucosa arising in a tubulovillous adenoma. The cauterized base of the stalk appears free.

**Case #5**  
**Ascending Colon**  
 75 yo WM  
 Personal Ho of Colonic Polyps



Ascending/cecum, mass: Tubulovillous adenoma.

**EMR advantages include:**

- Advanced dysplasia and most early neoplastic lesions can be treated with curative intent simply by local resection.
- Provides tissue specimen for histology and staging.
- EMR is a valuable adjunct to EUS to accurately determine intramucosal from submucosal tumor invasion (Case #6).
- Minimally invasive and carries lower morbidity and mortality compared to traditionally surgical approaches.
- Surgery can be performed after EMR if advance neoplasia or incomplete resection is detected on histology evaluation.

**EMR disadvantages are:**

- Is a labor intense, time consuming and requires advanced endoscopic skills.
- Large lesions (> 2 cm) can only be excised in piecemeal fashion which precludes evaluation for completeness of the resection at the lateral margins.
- Recurrence of neoplastic disease after EMR is a potential limitation.
- There is uncertainty regarding the long term outcome (lack of randomized trials directly comparing EMR vs. surgery).
- EMR is poorly reimbursed in the US.

The EMR technique consists of the suction(using transparent cap) or injection of a solution into the submucosa of the gastrointestinal wall to raise a lesion and separate it from the deep muscular layer allowing removal of tissue for further pathologic examination.

In contrast to surgical resection, EMR allows lesions to be removed with a minimum of cost, morbidity and mortality.



**Senthil Meenrajan, M.D.**

**Assistant Professor of Medicine,  
General Internal Medicine**

**Associate Program Director,  
Internal Medicine Residency**

The GME corner provides me the unique opportunity to reach everyone in a number of ways – sometimes just as a reporting corner to update everyone of progress made, sometimes as a tool to query readers and sometimes as a corner to reflect on a topic. This time I would like to do all three! Interspaced in this entire column are favorite phrases from different prominent leaders in our institution. If you know the answers feel free to e-mail them to me or Jaime.

Practice based learning (PBL) – this has become a key phrase in everything we do. Hopefully no one reading this right now is asking ‘what’s that’? As learners, educators and administrators we should have heard the phrase in many different situations. From how we learn to how we teach to how we practice medicine PBL has become an integral part of everything we do. Learning more from how our residents prepare and perform in the past has helped us improve our 3 year rolling average board pass rate from 70%, not too long ago to 88% at the end of this year. PBL is not a new concept nor is it unique to medical practice. I would have loved to say here” Yogi Berra once said.....”, but then I would be doing what someone else loves to do (guess who?). The cornerstone

of PBL is reflective learning. In the Kolb’s learning cycle we go through 4 phases:

*Abstract Conceptualization* ⇔ *Active Experimentation*  
⇔ *Concrete Experience* ⇔ *Reflective learning*

and then based on the reflective learning process we return to new abstract conceptualization and the process and progress continues.

We are particularly adept at the first 3 phases of the learning process but are certainly lacking in the last reflective part. Reflective learning however really helps us “close the loop” (according to who?) Reflecting on how we screen applications and interview each season has helped us get stronger candidates each year. The results are tangible...more applications each year (>3600 this year), interns stronger in academics and in clinical medicine and intense competition at regional and national meetings. The residents have done well in all areas of scholarly pursuits as typified by our winning the poster presentation competition at the Florida ACP meeting at St. Pete Beach. The jeopardy team finished second in the state. Not bad for a place from whose title “the term asylum was dropped rather prematurely” (says who?)

PBL comes to us from many different sources – evaluations in GME, PQRI (physician quality reporting initiative). At this time PBL is also required for ABIM recertification in the form of practice improvement modules. So if you know all about PBL - great...if not, get onboard and learn it now!! There is no running away from it whether in academics or not.....welcome to the new world order of constant self evaluation and life-long learning.

## A CLINICAL CASE

**Karishma Ramsubeik, M.D.**

**Harry J. Griffiths, M.D.**

**Ghaith Mitri, M.D.**

### Arthritis in a patient with severe psoriasis: Narrowing the differential

#### CASE REPORT

An 84-year-old woman presented with a 1-week history of pain and swelling in her knees and hands. She had a past medical history significant for severe psoriasis and osteoarthritis (OA). The patient reported morning stiffness and swelling lasting more than 60 minutes. On examination, there was swelling, warmth, and tenderness

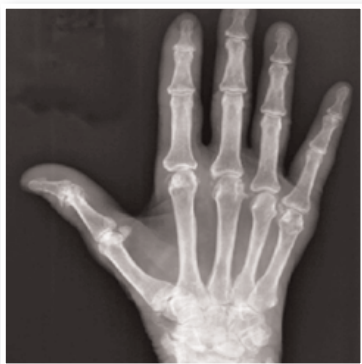at the proximal interphalangeal joints, metacarpophalangeal (MCP) joints, wrists, and knees. Heberden and Bouchard nodes were present. Skin findings included diffuse scaly, erythematous plaques consistent with severe psoriasis.

Therapy with prednisone, 60 mg/d, had been started by the hospital team 3 days before they consulted rheumatology, and the patient was already experiencing some relief. She did not have "sausage digits" or nail pitting, but her arthritis was symmetrical. She was taking only topical creams for her psoriasis, for which the diagnosis had been made more than 20 years earlier.

Considering the patient's symmetrical arthritis involving small and large joints with severe psoriasis, our top 2 considerations in the differential diagnosis were psoriasis and RA. Rheumatoid fac-

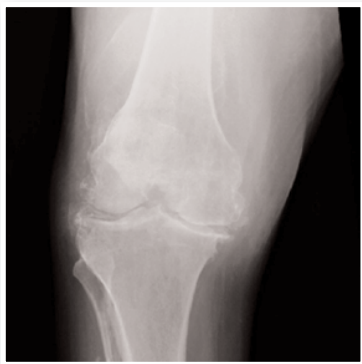Continued on Page 5

tor (RF) and cyclic citrullinated peptide IgG antibody test results were negative. X-ray films of the patient's hands revealed chondrocalcinosis in the triangular fibrocartilage, as well as in many of the MCP joints (Figure 1). In addition, there were severe degenerative changes throughout the carpus with marked scapholunate disassociation and narrowing of the triscaphe joint (between the scaphoid, trapezium, and trapezoid). On the basis of the imaging findings, a diagnosis of calcium pyrophosphate dihydrate (CPPD) deposition disease was made.



**Figure 1:** A radiograph of our patient's hand shows chondrocalcinosis in the triangular fibrocartilage as well as in many of the intercarpal and metacarpophalangeal joints. Severe degenerative changes have occurred throughout the carpus, with marked scapholunate disassociation.

X-ray films of the knees revealed chondrocalcinosis in the fibrocartilage (menisci) and in the hyaline cartilage outlining the femoral condyles and tibial plateaus (Figure 2). This finding is unique to CPPD deposition disease, but the patient also had secondary degenerative joint disease.



**Figure 2:** A knee radiograph shows chondrocalcinosis in both the fibrocartilage (menisci) and hyaline cartilage outlining the femoral condyles and tibial plateaus. Severe secondary degenerative joint disease also is present in our patient.

Further testing showed a white blood cell count of  $8.5 \times 10^3/\mu\text{L}$  (normal range,  $4.5$  to  $11 \times 10^3/\mu\text{L}$ ); hemoglobin level,  $10.7 \text{ g/dL}$  (normal,  $12$  to  $16 \text{ g/dL}$ ); hematocrit level,  $37.7\%$  (normal,  $37\%$  to  $47\%$ ); platelet count,  $240,000/\mu\text{L}$  (normal,  $140,000$  to  $440,000/\mu\text{L}$ ); calcium level,  $8.3 \text{ mg/dL}$  (normal,  $8.6$  to  $10 \text{ mg/dL}$ ); phosphate level,  $2.9 \text{ mg/dL}$  (normal,  $2.5$  to  $4.5 \text{ mg/dL}$ ); magnesium level,  $1.8 \text{ mEq/L}$  (normal,  $1.8$  to  $2.6 \text{ mEq/L}$ ); C-reactive protein level,  $89 \text{ mg/L}$  (normal, lower than  $5$ ); erythrocyte sedimentation rate,  $127 \text{ mm/h}$  (normal,  $0$  to  $20 \text{ mm/h}$ ); uric acid level,  $7.4 \text{ mg/dL}$  (normal,  $3$  to  $8.2 \text{ mg/dL}$ ); vitamin D level,  $8.8 \text{ ng/mL}$  (normal,  $15.9$  to  $55.6 \text{ ng/mL}$ ); and parathyroid hormone (PTH) level,  $154 \text{ pg/mL}$  (normal,  $16$  to  $65 \text{ pg/mL}$ ). Because the PTH level remained elevated on repeated testing, an endocrinology consultation was requested; the endocrinolo-

gist made an additional diagnosis of vitamin D deficiency.

## DISCUSSION

The patient had symmetrical polyarthritis with a long history of psoriasis and severe arthritis. The presence of psoriatic dermal signs is not pathognomic for PsA, which may have several manifestations.<sup>1</sup>

PsA is a type of arthritic inflammation that occurs in about 30% of patients with psoriasis.<sup>2</sup> Symmetrical PsA accounts for about 15% of cases of PsA. Wilson and associates<sup>3</sup> observed that nail dystrophy, scalp lesions, and intergluteal and perianal psoriasis are psoriatic features associated with a higher probability of PsA.

In 2005, the Classification of Psoriatic ARthritis (CASPAR) study group put forth a set of criteria for the diagnosis of PsA.<sup>4</sup> To meet the CASPAR criteria, a patient must have inflammatory articular disease (joint, spine, or entheses) with 3 or more points from 5 categories.

Current psoriasis is assigned a score of 2; all other features have a score of 1. The CASPAR criteria have a specificity of 98.7% and a sensitivity of 91.4%.<sup>4</sup> Our patient had a score of 3 points, making a diagnosis of PsA a possibility.

Regardless of the criteria, many patients may have PsA without skin disease; isolated nail psoriasis is observed in 3% of the patients with psoriasis.<sup>5</sup> Note that most criteria were intended as clinical research inclusion criteria and not diagnostic criteria.

RA would be a possibility in the differential of symmetrical PsA. However, the American College of Rheumatology (ACR) criteria, in which at least 4 of 7 findings must be met, should be considered.<sup>6</sup> Our patient met 3 of the 7 ACR criteria. Therefore, she did not qualify for a diagnosis of RA. The patient would have been characterized by this diagnosis if her RF had been positive, which is not uncommon in her age-group.

Crystal-induced arthritis usually is monoarticular. However, polyarticular acute flares are not uncommon and many joints may be involved simultaneously or in rapid succession.

Our patient had an inflammatory arthritis. Therefore, crystal arthritis—including gout—was included in the differential diagnosis. According to the American Rheumatism Association, a patient has gout if at least 7 of 13 criteria are present.<sup>7</sup>

An arthrocentesis would have been useful, because the diagnosis of gout includes the presence of intracellular negatively birefringent monosodium urate crystals, but was not performed for our patient. However, the patient's x-ray films lacked the classic findings of gout and the history was not suggestive of the condition.

In addition, although elevated serum uric acid levels are an important risk factor for gout, they neither confirm nor exclude the disorder. During acute attacks of gout, serum uric acid levels may be normal; conversely, many persons with hyperuricemia do not have gout. In fact, psoriasis with high tissue nucleic acid turnover also

may lead to mild to moderate hyperuricemia.<sup>8</sup>

Chondrocalcinosis—a pathological and radiographic term denoting stippled calcification of cartilage within joints, including both hyaline articular cartilage and fibrocartilage—usually affects middle-aged and older persons. A review of the literature suggests that this nomenclature involves an area of confusion. Chondrocalcinosis is not synonymous with CPPD crystals. The term also may refer to dicalcium phosphate dihydrate crystals or calcium hydroxyapatite crystal deposition disease (HADD). However, CPPD crystal deposition accounts for about 95% of chondrocalcinosis cases.<sup>9</sup>

The occurrence of intra-articular chondrocalcinosis also may be associated with OA.<sup>10</sup> However, plain x-ray films are not very sensitive for the diagnosis of chondrocalcinosis; in fact, Fisseler-Eckhoff and Müller<sup>11</sup> showed that a radiographic diagnosis of chondrocalcinosis is made in only about 40% of patients who have pathologically proven CPPD crystal deposition.

CPPD disease is characterized radiologically by the presence of chondrocalcinosis or involvement of an unusual joint or both. The classical radiological features in the wrist include calcification of the triangular fibrocartilage between the distal ulna and the carpal bones. There also may be solitary narrowing of the radiocarpal joint, which may progress to narrowing of the triscaphe joint. Chondrocalcinosis also may progress and be seen in the ligaments between the various carpal bones, particularly in the scapholunate and lunotriquetral joints but also on the metacarpal heads and in the interphalangeal joints.

In the knee, apart from the presence of chondrocalcinosis in both the fibrocartilage and hyaline cartilage (a finding unique to CPPD), the most characteristic finding is solitary narrowing of the patellofemoral joint without visible narrowing of the lateral or medial compartment. Chondrocalcinosis may be seen in other joints, including the hips, shoulders, and symphysis pubis. Note that chondrocalcinosis is a radiographic diagnosis and a radiological entity that may occur with or without clinical manifestations.

The most likely diagnosis in our patient, without our having performed aspiration, was pseudogout. The presence of CPPD crystals accounts for most cases of crystal-induced arthritis, apart from gout. The clinical presentation of CPPD crystal deposition is highly variable. Five clinical patterns have been described: asymptomatic, pseudogout, pseudorheumatoid, pseudo-osteoarthritis, and pseudo-neuropathic joint disease pattern; 50% of cases are idiopathic.

CPPD crystal deposition is thought to be associated with hypomagnesemia, hypophosphatasia, hyperparathyroidism, and hemochromatosis, but this possible association is controversial. A proposed mechanism of secondary CPPD crystal deposition in hyperparathyroidism is the associated hypercalcemia. The cause of CPPD crystal deposition is not known, but 2 mechanisms have been proposed, overproduction or decreased removal of CPPD crystals from cartilage and abnormality of the underlying cartilage collagen.

Treatment of patients with CPPD crystal deposition is geared

mainly toward symptomatic relief. Aspiration of large effusions, NSAIDs, intra-articular corticosteroid injection or oral doses of corticosteroids, and low-dose colchicine may be used. There is no medical treatment for calcium deposits or polyarticular and progressive degenerative changes. Successful management of hyperparathyroidism or hemochromatosis has not been shown to reverse chondrocalcinosis, but managing the disease correctly prevents future flares and worsening of the disease condition.

HADD is characterized by the deposition of calcium hydroxyapatite crystals in para-articular soft tissues, resulting in tendinitis and bursitis; the cause is unknown. Hydroxyapatite crystals have a characteristic amorphous paste-like appearance on x-ray films.

HADD was a possibility in our patient. However, it more typically affects middle-aged persons and men and has a different joint distribution (ie, shoulders), although calcifications may be found in every joint and multiple deposits are common.<sup>11</sup> HADD has been found to be associated with chronic renal failure, collagen vascular disease, and trauma.<sup>12</sup>

Our patient may qualify for systemic management of psoriasis, which may include methotrexate or biologic agents. However, managing her psoriasis may not help her arthritis. We lowered our patient's dosage of prednisone to 5 mg 3 times a day and then tapered it. We started therapy with colchicine, 0.6 mg twice daily, and supplemental vitamin D. The patient's symptoms have since improved.

## REFERENCES

- Adapted from *The Journal of Musculoskeletal Medicine*. Vol. 26 No. 9
1. Landells I, MacCallum C, Khraishi M. The role of the dermatologist in identification and treatment of the early stages of psoriatic arthritis. *Skin Therapy Lett*. 2008;13:4-7.
  2. Zachariae H. Prevalence of joint disease in patients with psoriasis: implications for therapy. *Am J Clin Dermatol*. 2003;4:441-447.
  3. Wilson FC, Icen M, Crowson CS, et al. Incidence and clinical predictors of psoriatic arthritis in patients with psoriasis: a population-based study. *Arthritis Rheum*. 2009;61:233-239.
  4. Taylor W, Gladman D, Helliwell P, et al; CASPAR Study Group. Classification criteria for psoriatic arthritis: development of new criteria from a large international study. *Arthritis Rheum*. 2006;54:2665-2673.
  5. Kaur I, Saraswat A, Kumar B. Nail changes in psoriasis: a study of 167 patients. *Int J Dermatol*. 2001;40:601-603.
  6. Arnett FC, Edworthy SM, Bloch DA, et al. The American Rheumatism Association 1987 revised criteria for the classification of rheumatoid arthritis. *Arthritis Rheum*. 1988;31:315-324.
  7. Wallace SL, Robinson H, Masi AT, et al. Preliminary criteria for the classification of the acute arthritis of primary gout. *Arthritis Rheum*. 1977;20:895-900.
  8. Pittman JR, Bross MH. Diagnosis and management of gout. *Am Fam Physician*. 1999;59:1799-1806, 1810.
  9. McCarty DJ Jr, Hogan JM, Gatter RA, Grossman M. Studies on pathological calcifications in human cartilage. I: prevalence and types of crystal deposits in the menisci of two hundred fifteen cadavers. *J Bone Joint Surg*. 1966;48A:309-325.
  10. Reuge L, Van Linthoudt D, Gerster JC. Local deposition of calcium pyrophosphate crystals in evolution of knee osteoarthritis. *Clin Rheumatol*. 2001;20:428-431.
  11. Fisseler-Eckhoff A, Müller KM. Arthroscopy and chondrocalcinosis. *Arthroscopy*. 1992;8:98-104.
  12. Hayes CW, Conway WF. Calcium hydroxyapatite deposition disease. *Radiographics*. 1990;10:1031-1048.

## Changes in the “Legible Prescription Law”.

Reprinted with modifications from *Drug Update, Volume 26 No. 4; May 2009*.

On July 1, 2003, the “Legible Prescription Law” went into effect<sup>1</sup>. This law was created to reduce prescription errors and keep Florida citizens and visitors safe. The specific statute, “Written Prescriptions for Medicinal Drugs”, is located in Section 456.42 of the Florida statutes, a chapter that addresses general provisions for health professions and occupations<sup>2</sup>.

When first enacted, the law required ALL prescriptions to have the date written out (i.e., January 1, 2009) and the quantity written in both textual and numerical formats [i.e., 30 (thirty)]. In 2006, the law was amended to include a provision to exempt electronically generated and transmitted prescriptions from the requirement to list the quantity in textual format<sup>2</sup>. Recently, on April 29, 2009, Bill 1868 was approved by both the Florida House and Senate amending the law again<sup>3</sup>. The changes are to become law on July 1, 2009, pending signing by the governor. Following approval, the requirement for the date (as an abbreviate month [e.g., Jan]) and quantity in textual format will apply only to controlled substances.

It is important to remember that this law only applies to prescriptions and not for medication orders written for hos-

pitalized inpatients. Also, the law does not specifically prohibit filling by a pharmacist if the requirements of this law are not met; however, a separate statute (893.04 Pharmacist and practitioner) is being updated to give direction to pharmacists if the textual quantity is missing. The statute states: “If a prescription includes a numerical notation of the quantity of the controlled substance or date, but does not include the quantity or date written out in textual format, the pharmacist may dispense the controlled substance without verification by the prescriber of the quantity or date if the pharmacy previously dispensed another prescription for the person to whom the prescription was written”<sup>3</sup>. If the prescription is illegible the pharmacist should call the prescriber for clarification.

### References

1. Frequently Asked Questions: Legible Prescription Law [Internet]. Florida Board of Medicine [cited 2009 May 22]. Available from: [www.doh.state.fl.us/mqa/MEDICAL/info\\_legibleprescriptionlaw.pdf](http://www.doh.state.fl.us/mqa/MEDICAL/info_legibleprescriptionlaw.pdf)
2. 456.42 Written Prescriptions for Medicinal Drugs [Internet]. 2008 Florida Statutes, Title XXXII: Chapter 456 [cited 2009 May 22]. Available from: [www.leg.state.fl.us/statutes/index.cfm?App\\_mode=Display\\_Statute&Search\\_String=&URL=Ch0456/SEC42.HTM&Title=->2008->Ch0456->Section%2042#0456.42](http://www.leg.state.fl.us/statutes/index.cfm?App_mode=Display_Statute&Search_String=&URL=Ch0456/SEC42.HTM&Title=->2008->Ch0456->Section%2042#0456.42)
3. Enrolled Senate Bill 1868: Relating to the Practice of Pharmacy [Internet]. The Florida Senate 2009 Legislative Session [cited 2009 May 22]. Available from: [www.flSenate.gov/cgibin/view\\_page.pl?Tab=session&Submenu=1&FT=D&File=sb1868er.html&Directory=session/2009/Senate/bills/bill\\_text/html](http://www.flSenate.gov/cgibin/view_page.pl?Tab=session&Submenu=1&FT=D&File=sb1868er.html&Directory=session/2009/Senate/bills/bill_text/html)

## NEWS & NOTES

### Dr. Santosh Kale, receives 2009 Shahin Award for Medical Research

Dr. Santosh Kale is the recipient of the 2009 Shahin Award for Medical Research, Review Category for his article *A Case and Literature Review of Complicated Gastrointestinal Stromal Tumors*, published in *Gastroenterology and Hepatology*. The decision of the committee was unanimous.

The award is given annually by the Duval County Medical Society (DCMS) to recognize young physicians for their scholarly efforts. The award was presented to Dr. Kale at the DCMS / Navy meeting on September 22, 2009.

Please join me in congratulating Dr. Kale for this honor.

### Top prizes for our residents at the Florida American College of Physicians (ACP)

Drs. Mohsen and Dr. Zhou, two of our residents in the core program have won joint first place in the poster presentation competition. They were chosen among over 25 other competitors.

In addition, our medical resident jeopardy team did well by finishing second in the state.

Congrats to the team.

### Update in Nephrology:

Hyatt Riverfront Hotel, February 20, 2010

Save the Date - A one-day program focusing on relevant current and emerging diagnostic and management issues for primary care providers pertaining to patients with kidney disease and hypertension.

### Diagnostic and Interventional Musculoskeletal Ultrasound for Rheumatologists:

Ponde Vedra Inn, March 5 - 7, 2010

An intensive skills workshop to improve accuracy of diagnosis and treatment. This course, with didactic, demonstration, and cadaveric sessions, addresses anatomy and imaging techniques of the upper and lower extremities and hips for the practicing Rheumatologist.

### Internal Medicine Update:

One Ocean, Atlantic Beach, March 12-14, 2010

This program is designed to provide general internists and subspecialists, family medicine physicians, physician assistants, nurse practitioners and allied health care professionals with a state-of-the-art update in Internal Medicine.

# We look harder. *We feel softer.*

At the Shands Jacksonville Advanced Breast Imaging Center at Emerson Medical Plaza, we've combined the soft comfort of a MammoPad™ with the latest digital technology. The MammoPad™ is a soft foam pad that creates a cushion between the breast and the mammography machine. All this with 3-D ultrasound technology for patients who need additional testing.

At the Shands Jacksonville Advanced Breast Imaging Center, patients have access to the best there is to offer — expert University of Florida physicians, state-of-the-art equipment and compassionate care.

We also offer:

*More Convenient Hours • Closer Location • Caring Staff*



**UF&ShandsJacksonville**  
The University Of Florida Health System

904.633.0275    [jax.shands.org](http://jax.shands.org)  
4555 Emerson St., Suite 120, Jacksonville, FL 32207

NON-PROFIT ORG.  
U.S. POSTAGE  
PAID  
JACKSONVILLE, FL  
PERMIT NO. 73

653-1 West Eighth St.  
Department of Medicine  
Jacksonville, FL 32209-6511  
904-244-8846; fax: 904-244-8844

College of Medicine

**UNIVERSITY of FLORIDA**

